PRACTICAL

OBSERVATIONS

ON

DISEASES OF THE EYE.

Plate 1.

1

3

2

4

1 David Grimmie's Eye previous to the operation

2 The same Eye a fortnight afterward

3 Mr. Menoe's Eye previous to the operation

4 The same Eye after the disease was cured.

Engraved by J. Hawksworth.

Published May 28th 1812, by Callow, Crown Court.

Sir Hayin Rayal 1827

PRACTICAL OBSERVATIONS

ON

ECTROPIUM,

OR

EVERSION OF THE EYE-LIDS,

WITH THE

Description of a New Operation

FOR THE

CURE OF THAT DISEASE;

ON THE

MODES OF FORMING

AN ARTIFICIAL PUPIL;

AND

THE DESCRIPTION OF

A SERIES OF

New and Improved Operations

FOR THE

CURE OF THE DIFFERENT SPECIES OF

CATARACT.

ILLUSTRATED BY COLOURED ENGRAVINGS.

By SIR WILLIAM ADAMS,

Member of the Royal College of Surgeons in London;
Oculist Extraordinary to His Royal Highness the Prince Regent;
Oculist in Ordinary to their Royal Highnesses the Dukes of Kent and Sussex;
Late Surgeon to the West-of-England Infirmary for curing
Diseases of the Eye, instituted at Exeter;
Corresponding Member of the Philomatique Society of Paris,
And Ophthalmic Surgeon to the Hospital for Invalid Seamen at Greenwich.

London,

PRINTED FOR J. CALLOW, MEDICAL BOOKSELLER,

CROWN-COURT PRINCES-STREET, SOHO;

COX, ST. THOMAS-STREET, BOROUGH; BRYCE AND CO. EDINBURGH;

AND GILBERT AND HODGES, DUBLIN.

1814.

SMITH & DAVY, Printers, Queen Street, Seven Dials.

WEST OF ENGLAND INFIRMARY,

Under the Patronage of their Royal Highnesses,

THE PRINCE REGENT AND DUKE OF KENT.

Established in Exeter, for Curing Diseases of the Eye.

PRESIDENT—Right Hon. EARL FORTESCUE,
(Lord Lieutenant of the County of Devon.)
VICE-PRESIDENT—SAMUEL FREDERICK MILFORD, Esq.
TREASURER—ROBERT RUSSELL, Esq.

COMMITTEE.

The Hon. and Right Rev. Lord Bishop of Exeter
Right Hon. Lord Clifford
Right Hon. Lord Clinton
Right Hon. Lord Rolle
Right Hon. Lord Grenville
Right Hon. Lord Graves
Right Hon. Lord Visc. Courtenay
J. P. Bastard, Esq. } *Members*
Sir Lawrence Palk, Bt. } *for Devon.*
Sir William Pole, Bart.
Sir Thomas Dyke Acland, Bart.
Sir John Kennaway, Bart.
Sir William Elford, Bart.
Sir John T. Duckworth, K. B.
James Buller, Esq. *M. P. for Exeter*
Admiral Schank
Albany Saville, Esq. M. P.
J. B. Cholwich, Esq.
Samuel Kekewich, Esq.
Thomas Porter, Esq.
Lambert Blair, of Courtland, Esq.
James White, of Fordland, Esq.
William Jackson, of Cowley, Esq.
John Milford, Esq.
Edmund Granger, Esq.
Rev. Canon Heberden
Rev. Mr. Tripp
Rev. Mr. Tremayne, Heligan
Warwick Hele Tonkin, Esq.
F. Glanville, of Catch-French, Esq.
Rev. Mr. Manning
James Buller, of Saltash, Esq.
John Manning, Esq.
Robert Kennaway, Esq.
Mr. Robert Trewman.

TO THE

PRESIDENT,

THE VICE-PRESIDENT, THE TREASURER,

The Committee,

AND OTHER GOVERNORS,

OF THE

WEST OF ENGLAND INFIRMARY,

FOR CURING

DISEASES OF THE EYE.

MY LORDS AND GENTLEMEN,

I SHOULD feel wanting in duty as well as gratitude, did I not embrace the opportunity which the present Publication affords me, of expressing my obligations for the promptitude and liberality with which you seconded

my views, when I first suggested the establishment of an Infirmary in the West of England, for treating exclusively diseases of the Eye; having previously obtained for such an Institution the sanction and patronage of His Royal Highness the Prince Regent.

It cannot escape your recollection, that, in obedience to the injunctions of some of its first and warmest friends, I was constrained very reluctantly to relinquish the general practice of Surgery; but candour requires me to acknowledge, that I have since had ample reason to be satisfied with the result; for, whatever may be found in the following observations, worthy

either the approbation of my Professional Brethren, or conducive to public benefit, may be in a great measure attributed to the attention which I have been able to devote to the Diseases of the Eye, in consequence of relinquishing general practice.

To you, therefore, my Lords and Gentlemen, as the first promoters of my exertions in this branch of my profession, and as the Guardians of an Institution which afforded me a very extensive practical experience, and in which the following operations originated, I gratefully dedicate this Work; with the anxious hope, that its publication will contribute to the relief of suffering humanity, and thus accord

with the objects which you have so liberally endeavoured to promote.

I have the honour to be,

My Lords and Gentlemen,

Your obliged and obedient

Servant,

WILLIAM ADAMS.

28, *Albemarle-Street,*
July 25, 1812.

PREFACE.

In the following sheets, it has been a principal object, briefly to describe my practice in the different diseases of which I have treated, and to relate the alterations and improvements in the operations which experience has suggested to me. When I have spoken of the practice of others, it has been done solely to elucidate the subject in discussion, or to point out in what respect it either coincides with, or differs from mine. I have therefore avoided swelling my Work by numerous quotations, which tend rather to show the researches of the author, than to increase the value of his practical remarks.

The Essay on Eversion of the Eye-lids, was intended for publication in the Edin-

burgh Medical and Surgical Journal; but having been sent too late for the last quarterly Number of 1811, I withdrew it, and have since added the chapters on Artificial Pupil and Cataract. The method proposed for the cure of Ectropium has neither been described nor practised hitherto, as far as I have been able to learn. To ascertain this, I have examined the works of the most eminent authors who have written on the subject, and have made extensive inquiries among my medical friends.

Although I am not indebted to any author, for the revival and improvement of Cheselden's operation for closed pupil, yet I think it proper to mention, that some time after I had practised the method of introducing the knife with its cutting edge backwards, to prevent the escape of the aqueous humour, I found the same mode described in Heister's Surgery.

I have, in the chapter on Cataract, described the operations applicable to all the species

which are commonly met with in practice. The more speedy solution of the cataract, when divided and placed in the anterior chamber, has been noticed by different writers: but this division does not appear to have been considered by any of them as essential; neither has there been any instrument described, nor any method proposed, by which the hard cataracts of old persons can be divided, so as to be placed with safety in the anterior chamber.

The different operations which I have recommended are, I believe, very generally known, wherever I have been called on to operate. While pursuing the operation taught me by my lamented friend and preceptor Mr. Saunders, I felt myself bound by every tie of gratitude and honour to observe the secresy he had enjoined; but, having found it necessary to abandon his practice, I then no longer hesitated to invite the most respectable members of the profession to witness my operations, in

order that they might form an estimate of their comparative merit with those in general use.*

It was my intention to have added to this work some practical observations on the different stages of the purulent inflammation of the conjunctiva in adults, commonly called the Egyptian Ophthalmia. I have however delayed their publication, in consequence of an opportunity recently afforded me, of establishing the general efficacy of my practice on the worst forms of the disease. His Royal Highness the Com-

---

* While in Dublin my operations were witnessed by the most respectable physicians and surgeons in that city; whose disinterested and friendly conduct I shall ever remember with sentiments of esteem and obligation;—and during a short stay in Edinburgh, on my return to England, the Surgeons of the Royal Infirmary, actuated by the same sentiments of liberality, requested that I would exhibit some of my operations for cataract, on patients in that Institution, which I had the honour of doing before them, and the numerous class of students belonging to the University.

mander in Chief having been graciously pleased to command my services, in the treatment of this disorder on some soldiers in the York Hospital at Chelsea,—in this extensive field of observation, where I have been seconded by the liberal co-operation of the Director-general Mr. Weir, the other members of the Army Medical Board, and the Medical Officers attached to the Hospital, many new facts may be developed, further opportunities of practical improvement may occur; and, as I am desirous of rendering my observations as complete as circumstances will allow, I am induced to withhold them from the Public at present, in the hope of hereafter offering them with their value enhanced by the delay.

CONTENTS.

	PAGE
Dedication	v
Preface	ix

CHAPTER I.

On Ectropium or Eversion of the Eye-lids	1
Modes of Treatment in common use, not equal to the cure of the worst stages of simple Ectropium	2
Description of this Form of the Disease	3
New Operation described for its Removal	4
Complicated Form of Ectropium described . . .	8
A compound Operation described for its Cure . .	10
Cases	12

CHAPTER II.

SECT. I.

On Contracted or Obliterated Pupil.

A concise History of Cheselden's Operation for Artificial Pupil, and the unfavourable Opinions entertained of it by various eminent Authors	21
Circumstances which led to its Revival and Improvement	25

SECT. II.

A Description of the Operation for making an Artificial Pupil where the natural one is much contracted or obliterated, and where the Lens has been previously removed	36
Ditto, for Obliterated Pupil, complicated with an Opacity of the Capsule, or Lens, or of both .	38
Ditto, for Obliterated Pupil with Opacity of the transparent Cornea	40

SECT. III.

General Observations 51
Cases illustrative of the Success of the different Operations for Artificial Pupil 62

CHAPTER III.

SECT. I.

On Cataract 99

SECT. II.

A description of Instruments 126
Operation for Solid Cataract in Children and Adults 132
Ditto for Fluid Cataract 137
Ditto for Capsular ditto 139
Ditto for Adherent Capsular ditto 141
Ditto for Solid Cataract in Old Persons 144
Ditto for Adherent Lenticular Cataract 147
Ditto for Capsular Opacity with a transparent Lens 148
After-Treatment 149

SECT. III.

General Observations 155
Cases illustrative of the efficacy of the different Operations recommended 183

POSTSCRIPT.

Observations on some Symptoms generally considered indicative of Amaurosis 249

FACTS AND OBSERVATIONS

ON

SOME IMPORTANT DISEASES OF THE EYE.

CHAP. I.

ON ECTROPIUM; OR, EVERSION OF THE EYE-LIDS:

With the Description of a new Operation for the Cure of that Disease.

FEW diseases of the eye, or its appendages, exhibit a more deformed appearance, or prove more distressingly painful to the patient, than Ectropium, or eversion of one or both of the eye-lids. The frequency of its occurrence, and the repeated attacks of acute inflammation of the eye-ball, as well as of the lid, produced by the exposure of a large portion of the conjunctiva to the influence of irritating causes, have attracted the attention of many professional men of the first celebrity; and different modes of treatment have been recommended for its removal.

Among others, Professor Scarpa proposes, in recent and slight cases of eversion, to destroy the conjunctiva, at the edge of the tarsus, with caustic; and, when the disease is more considerable, to extirpate the whole fungus close to the external muscular substance of the eye-lid, with the curved scissars; but he adds, that, in advanced life, the eye-lids are so much relaxed, that the disease may be regarded as altogether incurable. My own experience is fully in unison with that of the learned Professor, respecting the description of cases in which caustic may be advantageously employed; but, on the contrary, when the eversion is considerable, and consequently the tarsus much elongated, I have never found the simple excision of the fungus sufficient to effect a radical cure. It doubtless lessens the deformity; but as a certain degree of eversion still remains after this operation, the vessels, from repeated inflammation, again become so turgid and overloaded with blood, as by their weight and distention to re-produce the disease in as great a degree as before. Mortified at having myself failed, like others, in the removal of this deformity, I endeavoured, soon after the establishment of the West-of-England Eye Infirmary at Exeter, to which I was appointed Surgeon, to

devise some more effectual method of cure than any of those hitherto practised. With this view, I was led attentively to mark the appearance of the complaint in its most aggravated form, and to compare it with that of the eye-lids in a healthy state. The edges of the tarsi, if the upper and lower lids are free from disease, when the eye is closed, are very nearly parallel; but where the eversion exists in a considerable degree in the lower lid, its edge is forced down towards the cheek, and forms a line of a crescent like figure.*

In consequence of this morbid change in the parts, so much of the exquisitely sensible membrane of the eye-lid becomes everted, as to prove a continual source of pain and irritation to the patient, when exposed to heat or cold, sharp winds, dust, &c. Intolerance to a strong light, accompanied with an almost continual flux of tears, which chiefly flow over the cheek, and excoriate the integuments of the eye-lid and cheek, still further increase the sufferings of the patient. From repeated attacks of inflammation, which often give rise to opacities of the cornea, the conjunctiva at length becomes highly

* Vide Plate I. Fig. 1 and 3.

vascular, much thickened, and granulated in appearance: thus producing that disagreeable aspect which the complaint assumes under its worst form.

On first adopting the operation about to be described, I employed a very small curved bistoury, the point of which I carried along the inside of the eye-lid, at its outer angle, downwards and outwards, as far as the point of reflection of the conjunctiva would admit. I then pushed it through the whole substance of the everted eye-lid and its integuments, and cut upwards through the tarsus, making an incision nearly half an inch in length. With a curved pair of scissars I next snipped off a piece of the edge of the tarsus, about the third of an inch in width, and afterwards I removed, with the same instrument, the whole of the diseased conjunctiva, to prevent it from mechanically irritating the eye-ball. After the profuse hæmorrhage had ceased, I passed a needle and ligature through the whole substance of the two divided portions, and brought the raw surfaces as accurately into contact as possible. Finding, however, that too much integument had been left at the lower part of the incision, which formed a small knob

after the wound had cicatrised,* I substituted, in subsequent operations, in preference to the scalpel, a pair of straight scissars, with which I cut out an angular piece of the lid, resembling the letter V. This prevented the formation of the little protuberance, but the incision did not heal at its upper part by the first intention. It was, however, essential that this process should, if possible, be accomplished, since, independent of the delay that was thus produced in effecting the cure, the space between the two disunited edges of the lid became filled up by granulations, which in some measure conduced to the reproduction of the disease. As the frequent motion of the eye-lids, however, seemed to oppose the greatest obstacle to the adhesive process, by preventing the divided surfaces being accurately retained in contact, I left about a quarter of an inch of the lid adjoining its external angle; and, after shortening it as much as was necessary, brought the two edges into juxta-position, in which situation it was retained by means of a suture, which completely answered my expectations.† I have not specified the

* Vide Case II. † Vide Case IV.

length of that portion of the lid necessary to be removed, since this depends on the degree of elongation and consequent eversion, and must therefore in a great measure be left to the judgment of the operator. It may not, however, be here improper to caution the surgeon against too much shortening of the parts, as, in this case, they could not be brought into contact without stretching them to such a degree as to produce ulceration, thereby detaching the ligature before an union is effected. On the other hand, if too small a portion of the diseased parts be removed, so that the least eversion in the centre of the lid be suffered to remain, chronic inflammation will be likely to ensue, and the vessels becoming turgid will, by their weight and distention, again produce a morbid elongation of the tarsus, that must finally terminate in a recurrence of the disease. By an attention to these circumstances, none of the patients on whom I have operated, for this malady, have ever been subjected to a relapse. It has often surprised me, that this simple operation, which has proved uniformly successful with me, should not have occurred to Professor Scarpa, or, so far as I have been able to

discover, to any other of those ingenious practitioners who have professedly written on the subject *.

Purulent ophthalmia, whether occurring in children or adults, is often productive of eversion of the eye-lids. This variety of the disease, however, I dare venture to assert, may always be relieved by freely unloading the vessels by scarifications on the inner edge of the eye-lid, after the acute symptoms of inflammation have subsided. But should this highly important practice be too long deferred, the parts concerned in the production of the disease lose their tone, and become gradually more everted in proportion to the length of time it exists, and the

---

* Mr. Ware in the first volume of his Works on Diseases of the Eye, page 42, says, "This operation of removing a portion of the tunica conjunctiva from the inside of the everted eye-lid, is not only useful when the eversion is accompanied with an acute ophthalmy, but is also sometimes the only effectual remedy in those cases, which we vulgarly denominate "bleared eyes," where the eversion of the lid is unconnected with any considerable inflammation, and, from its long continuance, may be considered as a chronic disease. The only caution necessary to be attended to, by those who perform the operation, is to avoid wounding the cartilaginous edge of the lid, lest it leave after the cure, a notch or depression in this part."

frequency of the attacks of inflammation, till the conjunctiva is completely exposed. Hitherto my experience of its efficacy has however been confined to those cases of eversion arising from neglected lippitudo, or acute attacks of inflammation of the conjunctiva, which had been either wholly unattended to, or improperly treated. But the disease sometimes exists in a more complicated state, when it is caused by small-pox, burns, or scalds of the face, &c. In such instances, very firm adhesions are formed between the integuments of the eye-lid and those of the cheek, during the cicatrisation of the ulcerated parts. Frequently the conjunctiva is so much stretched, from the part where it is reflected over the eye-ball to its attachment at the edge of the tarsus, that the whole of the internal surface of the lower eye-lid is exposed to view.

Professor Scarpa is of opinion, that a complete cure can never be effected in this species of the disease, as that portion of the integuments which is destroyed cannot be re-produced, and that consequently some degree of deformity must remain, after the most successful operation, by the greater or less exposure of the eye-ball, in proportion to the

aggravation of the previous malady. He therefore recommends separating the whole internal membrane of the lower palpebra, by dissection, from its attachment to the edge of the tarsus, as near to its base as possible, and afterwards completely removing it. He objects to a simple division of the cicatrices, as he never, it would appear, witnessed a permanent elongation of the integuments produced by it. The contraction of the eye-lid towards the eye-ball, after the cicatrisation of the wound, I strongly suspect, will not be in general found sufficient to cure, or even materially to alleviate the disease, where the eversion and contraction of the integuments are considerable, since, besides the firm adhesions existing between the skin of the palpebra and cheek, from the lengthened state of the tarsus, some part of it must remain everted. A case of this kind, occasioned by a scald in the face, fell under my observation in the London Eye Infirmary, while I was a pupil, and acted as an assistant in that Institution. The conjunctiva was everted nearly half an inch, and gave the patient so much pain, when the eye was subjected to the influence of any irritating cause, that he had for some time kept it bound up. Mr. Saunders proposed an operation, as the only

means of affording relief, to which the man gladly assented. On the adhesion between the eye-lid and the cheek being carefully separated with a scalpel, the lid was replaced by the finger in its natural situation without any difficulty; but, the moment that support was withdrawn, it again fell back to its former position. By strips of adhesive plaister, the lid was kept up for some time tolerably well; but as soon as the wound began to heal, an union again took place between the divided parts, which produced nearly as much deformity as before. Having left London shortly after, I am ignorant whether any further effort was made to relieve the patient. The failure of success in this case appeared to me, in a great measure, to arise from a want of support to the eye-lid to counteract the retractive disposition of the parts, during the cicatrisation of the separated integuments; and had Mr. Saunders been then acquainted with the plan I have ventured to recommend, and which I some time after communicated to him, I think the result would have proved very different. In this species of the disease I would recommend, that a free separation of the adherent parts should first be made in the manner practised by Mr. Saunders, and afterwards the

lid should be shortened, and brought into contact, as in a case of simple eversion. By the speedy union of the divided edges, the eye-lid will be retained in its place, and the danger of the integuments adhering to the cheek, be in a great measure prevented. The extended raw surface would most probably be covered by a new production of skin; but should even some degree of shortening of the integuments occur during the process of cicatrisation, and the edge of the tarsus be again somewhat pulled downwards, it will then be reduced to that stage of the disease, where the caustic or scissars may be employed with advantage. Should any disposition to a relapse be observed during the progress of the cure, pressure may be made by means of a soft compress on the lid against the eye-ball, by means of a monoculus bandage; and the after treatment should in every respect be the same as that directed in cases of simple eversion.

Sometimes the upper eye-lid also becomes everted from the same cause, which is still more unpleasant in appearance, and more distressing to the patient Fortunately, however, this is but a rare occurrence, as in my practice, which has been very extensive, I

have only witnessed a single instance of this complaint. The treatment should be similar to that above described in cases where this disease attacks the lower eye-lid.—

CASE I.

John Ford, of Witheridge in the county of Devon, aged 66, by trade a carpenter, was admitted an out-patient of the West-of-England Eye Infirmary, in the early part of November 1808, for an acute ophthalmia in his left eye, which began about ten days before he applied for relief at that Institution. On examination, I observed an opake circumscribed spot on the internal surface of the upper part of the transparent cornea; from which had exuded a considerable portion of coagulable lymph, that occupied the lower part of the anterior chamber. The patient complained of an acute pain in the eye, which extended over the whole side of the head, accompanied with great intolerance of light and redness of the adnata. He was immediately sub-

jected to a very rigid antiphlogistic plan. Besides copious and repeated bleedings from the arm and temporal artery, leeches, blisters, antimonials, and purgatives were successively employed. But though the strength of the patient was thereby so much diminished that he could scarcely walk without support, no effect whatever was produced in checking the disease; on the contrary, the effused fluid progressively augmented in quantity, until the whole anterior part of the eye became filled with it, when ulceration through the whole substance of the cornea ensued, and the entire organ was destroyed.

The lower lid of this eye had been completely everted for some years, in consequence of repeated attacks of inflammation, arising from neglected lippitudo. The edge of the tarsus formed a line resembling the segment of a circle, the most dependent part of which was more than one third of an inch from the angle formed by the conjunctiva, where it is reflected over the eye-ball. The temporal angle of the lid was more everted than the nasal, and could not be restored to its natural position by any degree of force the patient was able to bear. The everted conjunctiva had become granulated, morbidly vascular, and sensible to the

touch. Disappointed in my efforts to save the eye, I proposed an operation upon the eye-lid, to relieve him from the painful irritation caused by so much of the sensible conjunctiva being continually exposed. With this he gladly acquiesced.—I therefore, on the 20th of November 1808, in the presence of Mr. Nelson, a respectable surgeon of Durham, commenced the operation, by making an incision with a small curved bistoury downwards and outwards, through the extremity of the temporal angle of the lower eye-lid; with a curved pair of scissars I then cut off about one third of an inch of its elongated edge, and with the same instrument removed the diseased parts of the conjunctiva, which bled very profusely. The bleeding was promoted as much as possible, by the application of a soft sponge frequently dipped in warm water. As soon as the hæmorrhage ceased, I passed a crooked needle armed with a waxed thread through the tarsus, a little below its edge, then through the whole of the parts forming the lid at its outer angle; and after bringing the two raw surfaces accurately into contact, I tightened the ligature moderately, and lastly covered the whole eye with a plaister of simple ointment spread on lint. No inflammation ensued,

and on the fifth day after the operation, having observed, that the parts had completely united, I removed the ligature, and had the gratification of finding the lid perfectly restored to its natural situation. A little redness remained along its edge, but disappeared as soon as the conjunctiva healed. This took place at the end of a fortnight, when the patient was discharged, cured. He called on me twelve months after this, and I found every vestige of the disease entirely removed.

CASE II.

Mr. Menoe, ætat. 60, clerk in a Banking-House, No. 5. Granby Row, Dublin, consulted me about the middle of August, 1811, for a very bad case of eversion of the lower lid of his left eye, which, according to his account, was produced eleven years before in consequence of repeated attacks of inflammation. The pain and irritation of the eye and lid were very great, especially if exposed to cold winds, &c.: when the secretion of tears became sometimes so abundant, that vision was

not unfrequently for a while obscured by their copious effusion. The conjunctiva, as in Ford's case, was granulated, highly vascular, and sensible to the touch; but it was much more everted, and had a more disgusting appearance. The steps of the operation, and the after treatment pursued to effect a cure in this instance, were so precisely similar to that already described, that I deem it superfluous to repeat them.—On the fifth day, the ligature having become loose was removed, and I found an union every where effected, except at the edge of the tarsus. Some strips of adhesive plaister were passed along the face close under the lid from the nose to the ear, and by this means the small space which had not united by the first intention, became filled up with granulations, and the wound healed in about a fortnight. Owing to a great relaxation of the integuments of the eye-lid, a small prominence remained, * half the size of a pepper-corn; independent of which, this eye-lid looked as well as the other. Mr. M. was only prevented a week from attending his office.

---

* Vide Plate I, Figure 4.

CASE III.

David Crommie, of Lisnamulligi, county of Down, in Ireland, applied to me in Dublin, for an eversion of the lower eye-lid, about the middle of September, 1811.* He stated that, twelve months before, he had been attacked with an inflammation, and thickening of the upper lid of his left eye, which prevented him from raising it, so as to uncover the transparent cornea. This, after a short time, subsided; but soon afterwards the lower eye-lid was affected with redness along its edge, which by degrees became everted in the manner I saw it. He complained of suffering very acute pain, especially when the part was exposed to the influence of cold winds. The conjunctiva exhibited the same appearances as in the last-mentioned case. September 16th, I operated on him, in the presence of Mr. Smith, a respectable practitioner of that city, who was also present at the operation performed on Mr. Menoe. I proceeded nearly in the same manner before described; but, to avoid leaving too much integument, which might form an eminence similar to that noticed in the recital of Mr. M.'s case, I cut out an angular piece of the tarsus and lid, of the shape of the

letter V, and, after removing all the diseased conjunctiva, finished the operation as in the preceding cases. I next applied some strips of adhesive plaister across the face, to obviate the retractive disposition of the lid, and to prevent the ligature from ulcerating too soon. This excited some irritation and tumefaction in the integuments below the eye the next day, which were removed by the exhibition of two brisk cathartics at the interval of a day or two, and the application of folds of linen frequently moistened in a cold saturnine lotion. On the fifth day I removed the ligature, but, as in the last case, a small portion of the wound, at its upper part, had not then united. By supporting the lid, however, with adhesive plaister, this soon healed, leaving only a simple cicatrix *.

CASE IV.

William Lee, East-street, Manchester-square, was attacked with acute inflammation in both eyes in the beginning of April, 1811, and on the day following he became an out-patient to an Eye Infirmary. On the fourth day after his admission the

---

* Vide Plate I. Figures 1 and 3.

left eye suppurated, the cornea burst, and the organ was lost. The anterior chamber of the right eye also became filled with lymph or purulent matter, to discharge which an opening was made in the upper part of the cornea. Through this opening so much of the iris protruded, that the remaining aperture of the pupil does not exceed the size of a pin's head; but, happily for the patient, this operation saved the globe of the eye from total destruction. The violence of the inflammation, however, produced an eversion of both the lower eye-lids. The right eye was considerably more deformed than the other, and consequently more painful, when exposed to the action of any irritating cause, such as cold winds, dust, &c. Nearly as much of the conjunctiva was everted, as in Ford's case, and equally granulated in appearance. February 12th, I operated on the right eye by making an incision somwehat less than the third part of an inch from the external canthus, and cutting out an angular portion of the lid of rather more than the third of an inch in width; after which I removed all the diseased parts of the conjunctiva. I then brought the raw edges accurately into contact by means of a suture. Not the slightest inflammation ensued. On the fifth day after the operation I removed the liga-

ture, and found the wound perfectly united, except a small opening at the lower part, through which the tears escaped, and trickled down the cheek. I destroyed the edges of this, which appeared as if disposed to become fistulous, with the argentum nitratum, and thereby so much accelerated the healing process, that within a fortnight from the period of the operation the disease in the eye-lid was perfectly cured. The patient, though able to find his way without a guide, is nevertheless incapable of executing any kind of handicraft labour; on which account I have consented, at his earnest request, to perform the operation for closed pupil on his right eye at no very distant period. I did not, however, deem any operation advisable for the eversion of the left eye-lid, as it was unaccompanied with much pain, and as the eye itself was irrecoverably lost. In order to prevent the small opening at the bottom of the wound, which was in this case occasioned by my having placed the ligature too near the edge of the tarsus, the needle should be passed through the middle of the incised parts, which, by keeping them in close contact, will very probably in future effectually prevent the recurrence of a similar accident.

CHAP. II.

SECTION I.

ON CONTRACTED OR OBLITERATED PUPIL.

A CONCISE HISTORY OF CHESELDEN'S OPERATION FOR ARTIFICIAL PUPIL, AND THE OPINIONS ENTERTAINED OF IT BY VARIOUS EMINENT AUTHORS.

NO department of surgery can be deemed of greater importance than that which has for its object the restoration of sight to the blind. Hence those diseases which affect the organs of vision, and the adjacent parts, have in every age deservedly attracted a large share of the attention of surgical practitioners. Nevertheless, strange as it may appear, no operation for the relief of those persons labouring under a closure of the pupil, seems to have been attempted before the time of Cheselden. This celebrated surgeon has described his mode of operating nearly as follows, and illustrated it by plates, in the thirty-fifth volume of the Philosophical Transactions, page 451, published in the year 1735. The eye-lids being held open by a speculum, he then took a narrow and single-edged knife, and passing it through the sclerotica as in couching, he afterwards thrust it for-

wards through the iris, and in extracting it cut through the iris in the manner represented in the plate. If the disorder was not accompanied with a cataract, he considered it best to perforate the iris in the middle, otherwise when there was a cataract he made the incision a little higher in the iris, that the cataract might not obstruct the ingress of the rays of light *. The cataracts which accompany this disease, he supposed, were generally very small, and sometimes their adhesion to the iris so firm as to render it impracticable to couch or depress them. This operation, however, did not prove equally successful in the hands of his immediate successors, either in Britain, or on the Continent.

Mr. Sharp, speaking on the subject of artificial pupil, as practised by Cheselden, observes, "I would not mislead any one who shall practise an operation not yet much known in the world. I do confess that the danger of the iris separating from the ligamentum ciliare, or of the wound

* In this description of the operation given by Cheselden, it is only in the upper part of the iris that he recommends the opening to be made, when the disease of closed pupil is complicated with cataract; but in the plates annexed, the incision is represented in one case above, and in the other below the centre of the iris.

not enlarging sufficiently, do upon the whole make the event very doubtful. I once performed it with tolerable success, and a few months after the orifice I had made contracted, and brought on blindness again."

Warner remarks, that, "however ingenious that operation of dividing the iris may be thought (in case of an absolute contraction of the pupil, or of a perfect adhesion of the cataract to the iris), which was invented and recommended by that great operator Mr. Cheselden; I must confess, I never yet saw a single instance of success from it, and therefore cannot recommend it as an advisable operation under any circumstances whatsoever."

Scarpa, who, it must be recollected, appears to have had no personal experience of this operation, expresses his doubts of its ultimate success, on the authority of Janin, who relates two cases in which, "though he performed it with the greatest care, no advantage accrued to the patient, since, after the symptoms produced by the operation had subsided, he found, that in both patients the transverse opening made in the iris, with the cutting edge of the needle, had re-united and healed." * To the

* Maladies de l'Œil.

same purpose the younger De Wenzel observes, that, " though the simple incision did succeed in the case of the blind person mentioned by Cheselden, subsequent and repeated operations have proved that the fibres of the iris will close again, after they have been thus divided. My father, he continues, has had many instances to convince him of this fact; and it is in consequence of these, that in our practice we employ a different mode of operating."

In the Second Edition of Mr. Ware's Chirurgical Observations relative to the Eye, &c. published in 1805, p. 253, he gives his opinion on this subject, in the following note. " The Translator sees no good reason to dispute the veracity of Mr. Cheselden in his description of the present case. It was certainly possible for him to succeed in the way he has here mentioned. At the same time, the translator is of opinion, that the operation proposed by the Baron, which he thinks would naturally occur to every person who prefers the operation of extraction to that of depression, is much more likely to be attended with success."—The description of Cheselden's operation as quoted by De Wenzel in this work, and to which Mr. Ware's note refers, appears to me obviously inaccurate, and to be a translation

from "L'Eloge de Cheselden dans l'Histoire de l'Académie de Chirurgie, Paris 1778," tom. II. p. 115. This fact is, however, obvious—at that time Mr. Ware did not practise Cheselden's operation.

Such having been the general opinion, it cannot appear surprising that it should first have been disregarded, and at length wholly abandoned. Accident in a great measure first suggested to me the idea of reviving it. William Pike, of Widworthy, near Honiton, Devon, was admitted a patient of the West-of-England Infirmary for curing diseases of the eye, early in November 1808. He was affected with capsular cataracts, which had ensued after the unsuccessful performance of the operation of extraction in a general hospital. The pupil of each eye was nearly obliterated, and the rays of light were prevented from passing through the small apertures which still remained, by portions of capsule thickened and firmly adhering to the posterior part of the iris. I at first attempted with the flat part of my needle to separate the adhesions; but finding this impracticable, I turned the instrument edge-ways, and with the point cut through the capsules, thereby making an aperture in each, sufficiently large to enable the man to see the minutest objects with the assistance of proper glasses. The fortunate result

of this operation encouraged me to hope, that with one of my cataract needles made very sharp, I might be able to divide the fibres of the iris, in a similar manner, in a case where the pupil was closed. An old man of the name of Heard, from the parish of Bow, Devon, who had also undergone the operation of extraction for cataract in the same general institution as Pike, afforded me an opportunity of carrying this design into execution. So much of the iris had protruded through the opening made in the cornea in consequence of this operation, that the superior margin of the pupil adhered to the cicatrix of the cornea, by which the iris was considerably stretched; and the patient (who could scarcely distinguish light) had suffered so severely from pain and inflammation, that I expressed my fears to him, that the retina was much diseased, if not entirely insensible. He was, however, exceedingly anxious to undergo any operation which might afford the least chance of obtaining relief; and as I was desirous of making a trial of the plan just mentioned, I acquiesced in his request, though under such inauspicious circumstances. Accordingly, in the beginning of December 1809, assisted by my nephew, Mr. Hockin, I made a division of the iris, exactly in its centre—the radiated fibres immediately retracted, and formed

an opening of a large size, nearly circular, and quite clear. From the great sensibility which the iris is generally supposed to possess, I was much surprised to find, on inquiry of the patient, that the operation gave him little or no pain ; but I have since almost uniformly observed this to be the case. As no inflammation succeeded, I examined the eye on the following day, when my apprehension appeared to have been too well founded, for the man could not perceive light better than before.—The result of this operation, although of no advantage to the patient, yet evinced to me the practicability of making a permanent aperture in the iris.

I therefore entertained a sanguine hope that if this operation were performed on an eye in which the retina was in a sound state, it would prove perfectly successful. In the spring of 1809, I operated on Richard Bligh, the pupil of whose left eye was not larger than the head of the smallest pin ; in whom my expectations were realized to their fullest extent, for, as will be seen in Case 11, he was allowed to return home at the end of six weeks, perfectly cured, and has since resumed his trade as a shoe-maker. Immediately on his discharge I communicated to my friend Mr. Saunders the manner in which I had per-

formed the operation, and the progress of this patient's convalescence. To this letter he favoured me with the following reply.

Ely Place, June 19th, 1809.

My dear Friend,

I am happy in the success of your operation in the case of cataract with adherent iris. As far as that case goes, nothing can be said against it—but not knowing in what degree the adhesions existed, or how far the capsule had been thickened, I cannot judge of the universality of its success. I am sorry to check any expectations of yours, *but certainly in a great number of cases it cannot succeed.* I succeeded happily myself in an anomalous case of a child born blind with pupils fixed, and certainly neither bigger than a good pin's head, by passing the instrument between the irises and capsules and disengaging them. The case has succeeded, as well as any other of my cases, in regard to vision; both pupils are circular, larger than before the operation, but fixed—yet I do not think that, generally speaking, one can disengage such adhesions. I tried your plan yesterday, but expect no

success, for the vitreous humour was in so diseased a state that the eye was drained and became flaccid on the escape of a fluid by the side of the instrument during the operation. I am inclined to think that a certain condition of the parts is requisite to bring success in your operation—viz. that the capsule must not be inordinately thickened, or too much combined with the iris. I think, in the operation above spoken of, I should have succeeded by the division of the iris, as you did in your case. However, I shall give it a fair trial in such probable cases as may come in my way.

Your sincere friend,

J. C. SAUNDERS.

The success which had attended these my first attempts to revive an operation that had so long been deemed either impracticable or useless by the highest professional authorities, both at home and abroad, acted as an additional stimulus to my exertions, while the situation I filled in the Exeter Infirmary for diseases of the eye afforded me the most ample means of extending this practice.—Notwithstanding the sanguine hopes I entertained, more than twelve months elapsed before I again

succeeded in a case of this kind, though, during that period, I had frequent opportunities of operating in cases of closed pupil complicated with cataract. By attentively reflecting on these failures I became acquainted with several causes which concurred to prevent success. One of the principal was the want of an instrument well adapted to this purpose. With the cataract needle I could not cut through the iris by a gentle force; and if I ventured to apply a greater force, the iris separated from its attachment to the ciliary ligament, which rendered all further attempts to effect a central aperture useless. The same accident appears to have happened to Mr. Sharp in his trials of this operation. In the hopes of procuring an appropriate instrument, I twice went to London, at the interval of a few months; but, though I described to different instrument-makers the purposes for which it was intended, still I could only procure the needle which cuts on one edge, and the spear-pointed knife, of different sizes, described by Cheselden. At length it occurred to me, that the curved edge of the common dissecting scalpel was well adapted to cut with facility. I therefore, when in London a third time, got a small knife made, two-thirds of an inch in length, and nearly

a line in width, with a straight back, sharp point, and a curved edge, which cuts back towards the handle for about three lines. * This instrument passes through the coats of the eye and iris with great ease, and when constructed conformably to this description will, I am confident, answer every purpose for which it is intended.

In March 1810, during one of my visits to London, I met Mr. Ware in consultation in the case of Lady W*****, (the initial of whose name I am here permitted to insert), who labours under closed pupil, complicated with cataract and amaurosis. I then related to Mr. Ware the result of my first operations, and explained to him the manner in which they had been performed. I also mentioned the circumstances which I conceived had induced the generality of surgeons to relinquish the operation of Cheselden, and pointed out the manner in which these might be obviated. In the course of the same conversation, I expressed a confident expectation, that if I could obtain the instrument I wished, the disease of closed pupil would no longer continue so intractable as it had hitherto proved.

---

* Vide Plate III. Fig. 1. 2.

Mr. Ware appeared so incredulous on the subject, that he seemed almost to doubt the facts I had stated, and by no means acquiesced with me in the general inferences I had deduced from them. In the following June, at his own house, I again renewed the subject of artificial pupil, but found his opinion unchanged. At this time I put into his hand a copy of the first annual report of the West-of-England Infirmary for curing diseases of the eye, published November 1st 1809, more than twelve months before the appearance of Mr. Gibson's work on artificial pupil, in which is recorded a vote of thanks given to me by the respectable Committee of that Institution, "for having practised an operation with perfect success in the case of closed pupil complicated with cataract, very few cases of which, as this meeting is informed, are recorded in the annals of British surgery."

Though much deference is unquestionably due to the opinions of Mr. Ware on subjects connected with diseases of the eye, yet in the present instance I confess they left no impression on my mind unfavourable to the operation in question. It is with the greatest satisfaction I am able to add, that further experience has fully justified the hopes I then en-

tertained, as I have, since the period of which I am speaking, performed that operation, in a very considerable number of cases of obliterated pupil, with the most perfect success. Whether from the successful cases recorded in the second report of the West-of-England Eye Infirmary, which by order of the Committee was published in the newspapers, or from whatever other cause I know not, but I have great satisfaction in observing that a complete revolution has, since the period above alluded to, taken place in the opinions of Mr. Ware on this subject, if I may be allowed to judge from the alteration made in the note on artificial pupil, quoted in the foregoing part of this chapter, p. 24, and which is inserted in the third edition of the same work, published in November 1811, in the following words :—" The translator sees no good reason to dispute the veracity of Mr. Cheselden, in his description of the present case. It was certainly possible for him to succeed in the way he has here mentioned; and the translator particularly recommends the operation in those cases where the pupil has become closed after the extraction of the cataract. In these, the opaque crystalline having been removed, it is most probable that the imperforate iris forms the only impediment to the passage of light to

the retina ; and the iris being stretched by the closure of the pupil, its division, in the way recommended by Cheselden, gives its fibres an opportunity to retract, which they generally do to a considerable extent. The translator has repeatedly performed the operation with perfect success: scarcely any inflammation having been excited by it, and vision becoming as perfect as after the most successful removal of the cataract."*

---

* In a small pamphlet also, published in November 1811, Mr. Ware speaks still more decidedly in favour of Cheselden's practice. "Baron De Wenzel (he observes) objects to the operation proposed by Cheselden, as ill adapted to accomplish the object intended by it. I beg leave to observe, however, that when the pupil has become closed after an unsuccessful operation of extracting the cataract, I have in several instances made a new pupil, agreeable to Cheselden's mode of performing the operation, with the most perfect and striking success. The fibres of the iris retracted as soon as they were divided, and left the pupil very nearly of its natural size. Its shape was not quite round; but the sight was immediately restored, and to so great a degree, as to enable the patient, by the help of suitable convex glasses, to see distinctly both near and distant objects, neither pain or inflammation being consequent on the operation."

HAVING now faithfully detailed the circumstances which led me to the adoption of Cheselden's obsolete operation, I trust (although unexpectedly anticipated in its communication to the Public) I have satisfactorily shewn that I have not been indebted to the works of any other author for its revival and improvement. By the various alterations which I have made in this operation, I have been enabled to render the practice of it applicable to every morbid state of the eye requiring an artificial pupil. I shall next proceed to give a description of the operations requisite in these various states, and afterwards subjoin some general remarks on the subject, together with some cases illustrative of their efficacy.

SECTION II.

A DESCRIPTION OF VARIOUS OPERATIONS APPLICABLE TO THE MORBID STATES OF THE EYE REQUIRING AN ARTIFICIAL PUPIL.

Simple Contraction or Obliteration of the Pupil.

A PARTIAL or total obliteration of the pupil frequently succeeds the removal of the crystalline lens. When the closure arises from a considerable protrusion of the iris through the section in the cornea, in consequence of an escape of the vitreous humour during the operation of extraction, or that it proceeds from supervening inflammation after accidental wounds of the eye, or after the texture of the lens has been freely broken up by the operation of couching, it is termed a simple obliteration of the pupil. In all cases where the lens has been thus removed, and the cornea is free of opacity, the division of the iris should be made in the centre, and should extend across two-thirds at least of its transverse diameter. The patient being seated

as in the operation for cataract, and the eye rendered steady by a gentle pressure with the concave speculum,* placed under the upper eye-lid, the artificial pupil knife should be introduced through the coats of the eye about a line behind the iris, with its cutting edge turned backwards instead of downwards. The point is next brought forward through the iris somewhat more than a line from its temporal ciliary attachment, and cautiously carried through the anterior chamber until it has nearly reached the inner edge of that membrane, when it should be almost withdrawn out of the eye, making a gentle pressure with the curved part of the cutting edge of the instrument against the iris in the line of its transverse diameter. If in the first attempt the division of the fibres of the iris is not sufficiently extensive, the point of the knife is to be again carried forward, and similarly withdrawn until the incision is of a proper length, when the radiated fibres will immediately contract, and an opening of a large size will be formed. After the operation is thus completed, the eye should be covered over with a plaister of simple ointment, spread on lint, and the patient

* Vide Plate III. Fig. 6 and 7.

put to bed with his head raised high.* The after treatment is the same as that fully described in the Chapter on Cataract, to which I refer my readers.

Obliterated Pupil complicated with Cataract.

From wounds of the eye-ball, but more frequently from inflammation of the iris, an obliterated or a very contracted pupil exists complicated with an opacity of either the lens or its capsule, and often of both. The primary steps of the operation are the same in these as in the simple cases. I take care, however, very freely at the same time to cut the cataract in pieces. Some of these I bring forward into the anterior chamber, and leave the remaining portions in the opening of the iris newly formed by the operation. These act as a plug in preventing its re-union by the first intention, and contribute to assist the radiated fibres in keeping the pupil more extensively open. In the course of some weeks, when the opaque lens is absorbed, all disposition to re-union in the divided iris is entirely done away.† When the disease has existed for a

* Vide Cases 5—10. † Vide Cases 11, 12.

number of years, I have generally found the capsule so very dense, and considerably thickened, that the vitreous humour has not afforded sufficient resistance to enable me to open or divide it. In such cases I formerly depressed both capsule and lens without division; but as they always returned to their former situation, unless when the vitreous humour was disorganized,* I now make it an invariable rule, in order to prevent this unfavourable consequence, to cut them in pieces by a subsequent operation, by which means they become dissolved and absorbed. In some instances, arising either from accident, or some unknown spontaneous cause, the lens has been absorbed, leaving nothing but the opaque capsule, which in every case of obliterated pupil from inflammation of the iris, is firmly adherent to the posterior part of this membrane. The capsule, as well as the iris, should be here first completely divided, and the former membrane being liberated from its adhesions, with the point of the instrument, should if possible be cut in pieces, and pushed into the anterior chamber, where it will become absorbed.† If, however, it is so much thickened that it cannot easily be divided, it may be

---

* Vide Case 15. † Vide Case 14.

forced out of the axis of vision without any fear of its return.*

Obliterated Pupil with Opacity of the transparent Cornea.

The transparent cornea, from different species of inflammation, and from various other causes, is frequently subjected to ulceration, which penetrates either wholly, or in part, through the substance of that coat. On the healing of the ulcer, an indelible cicatrix remains, which renders opaque that part of the cornea which has suffered from ulceration, and prevents the transmission of light through the diseased surface. In some cases the iris has protruded to such an extent, through an opening made in the cornea by the ulcerating process, as to occasion a partial or total obliteration of the natural pupil ; in others, the ulceration has extended so far on the external surface of the cornea, as to produce an opacity which totally obscures the pupil.

Both these events often occur ; and, in the former case, an artificial opening in the iris should be made op-

---

* Vide Case 7.

posite to the remaining transparent part of the cornea, wherever that may be found: but for the purposes of vision, the preferable parts are the external or lower margin of the iris, as well in these as in every other case where the centre of the cornea is opaque, and they are also the best adapted for the easy performance of the operation. If the opacity does not obscure more than one-third of the diameter of the cornea, I practise the operation as described for closed pupil complicated with cataract, and make the newly-formed opening extend from the opacity as nearly to the edge of the sclerotic coat as possible. The crystalline lens, whether transparent or opaque, is then cut up, and a part placed in the opening of the iris, to act as a plug.* This is my method of practice where the opacity is not very extensive; but when there is not above a line of the circumference of the cornea remaining clear, I then introduce the knife, though in a similar manner, at the external and upper part of the eye, in order to prevent the escape of the aqueous humour before the operation is completed, and make a perpendicular incision through the outer margin of the iris opposite to and extending

---

* Vide Case 16.

the whole length of the remaining clear part of the cornea.* This operation much resembles that recommended by Professor Scarpa for artificial pupil, with this difference, that the instrument is introduced through the coats of the eye in a different part, and the fibres of the iris are divided, instead of being detached from its ciliary ligament. But if, as has happened in some of those cases, the iris separates from its ciliary attachment, my operation becomes similar to that of Scarpa. Sometimes there is only a small protrusion of the iris, which adheres afterwards to the cornea, causes the edge of the pupil to be of an irregular form, and prevents its expansion beyond the limits of the cicatrix, by which vision is either partially or wholly obscured. In this case, if the disease is uncombined with any other morbid affection of the pupil, and the cicatrix is not of a large size, the operation should consist in introducing the artificial pupil knife through the cornea, a little anterior to the iris, and carrying its point on to the adherent part, which should then be divided with the cutting edge of the instrument. This accomplished, the iris immediately recedes to its proper

---

* Vide Case 17.

situation, and the pupil will again recover its natural size and powers. But if in addition to the adhesion the pupil be considerably contracted, or entirely obliterated, the operation, as for central pupil, must be performed opposite to a clear part of the cornea, and the point of the knife brought forward through the newly-formed aperture into the anterior chamber, and all adhesion between the cornea and iris separated. * Where the cicatrix is small, and there is no adhesion of the iris to the cornea, great benefit may be derived from applying a drop of a solution of belladonna within the eye-lids every morning. The rays of light which (by the great dilatation of the pupil) are thus enabled to pass to the retina round the circumference of the opacity, are sufficient to afford very useful vision, by which I have seen a person read with facility the smallest print while the iris was under the specific influence of this application, who at other times could not see to avoid the largest objects. A question naturally arises here. Will not the belladonna so applied either produce dangerous consequences, or entirely lose its effect by frequent repetition and long use? From the extensive expe-

---

* Vide Case 8.

rience I have had of its powers during the last ten years, I am strongly impressed with the belief that no ill consequence is to be dreaded, as I have every reason to feel convinced, that, instead of sympathetically producing an enlargement of the pupil, by first acting on the retina, as some have supposed, its operation is limited to the radiated fibres of the iris, to which it affords, for a certain time only after each application, its specific effect.* Like all other stimulants, it will lose its power by continued repetition; but it is remarkable, that after its application has been suspended for a while, it regains its accustomed influence. The man who forms the subject of Case 16, had used it for more than two years; but finding it no longer produce any effect, he laid it aside for a short time, and resumed it soon after my arrival in Dublin, when it acted as powerfully as before. But to proceed with my sub-

---

* This was the opinion of the late Mr. Saunders, as will be seen in his paper on Inflammation of the Iris, first published in the London Medical and Surgical Journal for July 1806; also that of our mutual professional preceptor, the late Mr. Hill, of Barnstaple, in whose practice, I believe, Mr. Saunders first saw the belladonna used.

ject. It often happens that the cicatrix in the cornea is so large as to reach beyond the utmost extent of dilatation of the pupil, even when under the influence of belladonna: yet, if the whole surface of the cornea is not obscured, an attempt may then be made either to open a new aperture in the iris opposite to the remaining unobscured part, according to the plan proposed by the late Mr. Gibson, of Manchester,* or to drag the natural pupil on one side. In cases of this kind, I however very much prefer the latter plan, because in the operation recommended by Mr. Gibson, the incision made in the cornea must be of such extent as probably to produce a considerable opacity in the portion of it which still remained

* Mr. Gibson, with a broad cornea-knife, makes an opening in the cornea, a line anterior to its junction with the sclerotica, about three lines in extent. Through this opening the aqueous humour escapes, and is generally followed by a part of the iris. If this membrane does not protrude sufficiently of its own accord, he makes some degree of pressure on the eye-ball; and when it forms a little bag of the size of a large pin's head, he cuts it off with a pair of fine curved scissars. The iris then recedes within the eye, and the portion which has been removed will leave an artificial pupil more or less circular.

transparent; and this objection, which is candidly acknowledged by Mr. Gibson, page 99 of his valuable Observations upon Artificial Pupil, I saw very strongly exemplified in the case of Mr. Rushton, of Liverpool, who had been operated on by that distinguished surgeon. The artificial pupil, which was of a small size, was seated quite at the bottom of the external margin of the iris; others, which the patient informed me had been made above it having been successively obscured by as dense an opacity as that which originally affected the centre of the cornea; and this opacity encroached even upon that part opposite to the upper portion of the pupil still remaining. In this operation* of

* In all the other operations recommended by Mr. Gibson in cases of obliterated pupil, the cornea is equally liable to opacity as in this; while from the necessity there is of introducing the point of the two-edged scalpel, or the iris scissars, and sometimes both, through the iris, for the purpose of removing a part of it, the capsule and lens must as certainly be rendered opake, if not previously so, as in any of my operations already described for artificial pupil, where the cornea is not only untouched, but the lens in most instances made useful in preventing a re-union of the divided iris.

Mr. Gibson's, it is true there is little risk of injury to the crystalline lens or its capsule; but the preservation of the lens can be of no advantage, if the inflammation occasioned by the incision made in the cornea be such as to render the whole portion of that coat opposite to the artificial pupil opaque.—Upon the authority of Mr. Gibson's publication, I made trial of his operation in two or three instances; but the unfavourable result induced me wholly to abandon it, and to substitute for it the following operation. To this I was led by Miss Russell's case,* by which it appeared to me that the original pupil might be so much dragged to one side (without any risk either to the transparent lens or its capsule,) as to be made subservient to vision by a very simple operation, namely, that of making an opening in the cornea of so small a size as neither to risk opacity, or to require the removal of any part of the iris. The unavoidable diminution which (after Mr. Gibson's operation) must occur in the size of the newly-formed pupil, when the natural one is much dilated, can never take place by pursuing this plan

* Vide Case 21.

first recommended.* I first fix the eye with a speculum, and then enter my closed pupil-knife through the cornea about a line anterior to the iris, and make the opening somewhat longer than the width of the instrument. Through this the aqueous humour will make its escape, and be followed by a part of the iris. If the iris does not protrude sufficiently from the pressure of the speculum, to extend the edge of the natural pupil as far as the puncture in the cornea, I lay hold of it with a pair of small forceps, and gently pull it out, using great caution not to employ so much force as to rupture it. Having in this manner dragged the outer edge of the pupil a little through the puncture, I do not cut off the protruded part, but suffer it to remain strangulated, which prevents it from again returning within the cavity of the eye. The puncture heals, and it includes

---

* I have not deemed it necessary to describe the various operations for artificial pupil proposed by different authors, with the exception of Professor Scarpa's; conceiving them more objectionable than those recommended by Mr. Gibson, as they all require a still larger opening to be made in the cornea, consequently the risk of inflammation and opacity is much greater.

the protruded part of the iris, which is shortly removed by a very weak solution of argentum nitratum, dropped into the eye two or three times a day. Care should be taken to make the incision no larger than just sufficient for the iris to protrude, in order to avoid the opacity which would be likely to ensue were it of a larger size, and also to prevent the iris receding when the cornea is again distended by the regeneration of the aqueous humour. In one instance even, where there existed a slight adhesion of the iris to the cornea, I was enabled successfully to accomplish this operation, after having first liberated the iris from its attachment.* If the pupils in both eyes be obliterated, and the corneæ opake, the openings should be made in the internal margin of the cornea of one eye, and the external margin of the other, because the motion of the two eyes being synchronous, the patient will thus see with both at once when viewing a lateral object; whereas, if each external part were the subject of operation, he would see but with one eye at a time.

In the description of the different operations

---

* Vide Case 18.

for artificial pupil, I have confined myself to the recital of facts, ascertained by my own experience. It will be obvious that I have assumed the existence of circular and radiated fibres in the iris. This opinion, though supported by many eminent anatomists, is not yet generally considered as established.

But it is foreign to the plan of the present Work to discuss any theories upon the subject; for, whatever may be the result of anatomical observations upon this question, the practicability and success of the operations, as illustrated by the cases referred to, will stand upon the evidence of facts against all hypothetical arguments.

SECTION III.

General Observations.

It should be recollected that Cheselden, in cases of obliterated pupil complicated with cataract, recommended an opening to be made in the iris above the edge of the cataract. He entertained an opinion that the cataract in such cases was generally of a small size, and that it did not always admit of a separation from the posterior part of the iris. Under this impression, and not fully acquainted with the solvent powers of the aqueous humour, his practice was as judicious as any that could have been suggested.—Subsequent inquiry has, however, shewn, that Cheselden was incorrect in his hypothesis as to the size of the cataract complicated with obliterated pupil, a person having a large lens being equally subject to a closure of the pupil as when the lens is small; and it is plain that he was not aware that the aqueous humour was endowed with so great a solvent power as it is now known to possess. In cases where the cornea is unobscured, a slight consideration of the structure

and form of that coat will shew the superior advantage of effecting a central opening in the iris. The cornea, from its convex form and transparency, is admirably adapted to the purpose of collecting and transmitting the rays of light, which, passing through the aqueous humour, are still further concentrated towards the natural situation of the pupil. Should therefore the artificial pupil be made in any part near the circumference of the iris, instead of its centre, vision must be comparatively imperfect, in proportion to its distance from that point.—This observation may be said to militate against making a lateral pupil; but surely, if by a mild operation a patient previously blind can obtain some useful vision, it is advisable for him to submit to it, though the nature of the case will not admit his seeing so perfectly as where the operation for a central pupil can be advantageously performed. Instead of depressing the crystalline lens, when I find it sufficiently soft to be cut in pieces, I make it useful by placing some portions within the edges of the wound, where, by keeping separate the cut edges of the iris, it effectually prevents their reunion. In two or three instances of closed pupil, in which I have operated

where the cataract was too hard to admit of this, I found the iris diseased, and considerably thinner in its centre than at the circumference, sometimes enabling me to see the opake lens through the greater part of its extent. In these cases, from the extensive central division of the iris, some of its diseased part having separated with the adherent capsule, and afterwards becoming absorbed, nothing but the rim of the iris has remained, leaving a pupil of a much larger size than when the lens admitted of division in the first instance.* It is obvious that a re-union of the iris cannot again take place where this occurs.—From the liability to re-closure in the newly-formed pupil, when the operation has been performed agreeably to the rules laid down by Cheselden, and which is evident from the quotations I have made from the works of so many eminent operators, it is probable there are some persons, notwithstanding all the caution with which my operations have been conducted and the success which has attended them, who may apprehend that at some subsequent period the artificial pupil, even thus made, may again become

* Vide Case 15.

closed. Three years have elapsed since I operated on Bligh, and there has been no disposition to a re-union of the fibres of the iris in his case, or have I heard of any of my other patients to whom it has happened. Indeed, the manner in which a closure of the pupil takes place, renders it impossible such an event can ever occur, unless an adventitious membrane be formed from a subsequent inflammatory attack, of which I have never seen but one instance.* An obliterated pupil is caused either by inflammation of the iris, or by a protrusion of a part of that membrane through an opening in the cornea. In the former case, which most frequently occurs, it is distinguished from inflammatory attacks of other parts of the eye, by the pupil becoming progressively smaller, and of an irregular form. At the same time, coagulable lymph having been effused from the posterior part of the iris, it at first simply agglutenates that membrane to the anterior surface of the capsule of the crystalline lens; but, if left to the natural course of the disease, it becomes in time organised, and permanent adhesions

---

* Vide Case 14.

are thus formed between the iris and the capsule during the contracted state of the pupil, which is consequently deprived of the power of expansion after the inflammation is removed. It appears then that two parts are necessary to produce an obliterated pupil in cases of inflammation of the iris, namely, its circular fibres or sphincter muscle, and the capsule of the lens. When the operation I have recommended is successfully performed, the circular order of the fibres are completely divided, and the capsule with its lens becomes absorbed. Thus then the two causes by which a closure of the pupil in inflammation of the iris takes place, are effectually removed. When obliteration arises from a protrusion of a part of the iris through an opening in the cornea, the remaining portion is so much stretched, that as soon as the central incision is made, the radiated fibres immediately contract, and leave an opening nearly circular, which can never again become closed. If, however, before the capsule is entirely absorbed, adhesions should again form between the iris and the capsule, and the newly-formed pupil be in consequence lessened in size, or entirely closed, the operation may be repeated as often as is necessary, without diminishing the

prospect of ultimate success, as the repetition will not produce any opacity in the cornea.*

By introducing the artificial pupil-knife with its edge downwards, and afterwards turning it backwards in the manner described by Cheselden, I found that a space was thus left by the side of the knife in the coats of the eye, through which the aqueous humour, and sometimes the dissolved vitreous humour, made their escape so copiously, as to cause a collapsion in the coats, whereby a division of the iris was rendered impracticable, which appears, from the same cause to have happened to Mr. Saunders. † When the knife is introduced in the manner I have recommended, this escape of the humours can but very rarely occur, until the operation is completed, and the knife withdrawn ; and it is then attended with no bad consequence, as the fluid that escapes becomes quickly regenerated. Another cause of the frequent failure of Cheselden's operation must have been the small size of the opening through the iris, made by one incision, which he does not recommend to be repeated. With the improved knife I now use, which cuts as sharp as a lancet, I have very seldom suc-

* Vide Case 13. † Vide Letter, inserted page 28.

ceeded by the first incision, but have repeated it in the manner already described, until the aperture in the iris is of a proper size. It is probable also, that in order to ensure success, the surgeons who unsuccessfully tried Cheselden's operation, made use of such a degree of pressure in withdrawing the instrument, as to cause a separation of the iris from its ciliary attachment, as occurred to Mr. Sharp. This consequence is much more likely to ensue, where an obliterated pupil is complicated with cataract, than where a closure of that aperture succeeds the removal of the lens, and should therefore in those cases be more particularly guarded against, and in repeating the cuts great care should be taken that the edge of the knife be confined to the same line in the iris, otherwise the margin of the pupil will be uneven, and the patient's vision very probably injured in consequence. On this account, this part of the operation requires a considerable share of steadiness both in the operator and the patient, as well as to avoid detaching the iris from the ciliary ligament; for if this should once occur, it will be impossible to effect a central aperture afterwards, the separation of the iris being increased by every further effort to accomplish the former object. A leading principle, which

I cannot impress too strongly on my reader's attention, and which should never be lost sight of in performing the operation for central artificial pupil, is to make a large division of the iris. No ill effects in respect to vision need be dreaded from its magnitude, as the eye-lids involuntarily become in part closed when the eye is exposed to a strong light, by which the superfluous rays are excluded, thereby performing the functions of the sound iris,* while a liability to a re-closure of the pupil, a contracted sphere of vision, and consequently a very imperfect sight, are the certain consequences of a small opening. This is strikingly manifest in John Mercer,† from whose eye, by repeated operations, performed with great skill and success, the cataract was removed, and the patient enabled to see minute objects distinctly, when placed immediately before him; yet, in consequence of no division having been made in the fibres of the iris, the pupil was so small, that the lateral rays of light were prevented from passing through it in sufficient quantity to enable him to avoid objects sideways by day, or to find his way alone with safety by night.

---

* Vide Cases 6 and 15. † Vide Case 10.

In all cases of artificial pupil, that aperture remains stationary. Its size will not be influenced by the application of belladonna, or by the strongest light. When the natural pupil has been closed for many years, the radiated fibres of the iris have generally lost in part their contractile power; and I have often found it useful, in such cases, to stimulate the iris with the point of my knife, and with it also to stretch open as much as possible the newly-formed pupil, where there was no lens to place within the edges of the wound; and I have sometimes observed, that the fibres, although at first immovable, have contracted in a day or two.* An obliteration of the pupil is often complicated with other diseased states of the eye, more especially a disorganised state of the vitreous humour, and a partial or total insensibility of the retina. The diseased state of the vitreous humour cannot be ascertained previous to an operation, unless part of the fluid is absorbed; the eye-ball is then diminished in size, and feels soft to the touch. If no absorption has taken place, though it may be perfectly disorganised, yet the distention of the coats, and

* Vide Case 9.

the consequent firmness of the eye, will be preserved. It is some consolation, however, to know, that all hope of rendering benefit, even in this complicated state of disease, is not lost, as may be seen in Cases 5 and 7. It is still more difficult, before the operation is performed, to ascertain the actual state of the retina. In some cases requiring central or lateral pupil, where the patients could see light and colours, and discern the motions of objects, they have derived no benefit from the operation, although it was perfectly accomplished; while, on the contrary, in others, when urged by the importunities of my patients, I have operated almost contrary to my judgment, the most favourable result has ensued.—The form of the artificial pupil varies considerably. When the crystalline lens has been previously extracted, the newly-formed opening is in general nearly circular; but where a closure of the pupil is complicated with an opaque capsule or lens, or with both, the artificial pupil will be of a transverse oblong shape.* The form, however, is of little consequence in respect to vision, as long as the opening is of a sufficiently large size.

---

* Vide Plate II. Figure 2.

Convex glasses, similar to those used after the operation for cataract, are always necessary in cases of artificial pupil; and great care must be taken, in their adaption to a lateral pupil, that the focal point be placed opposite to it, otherwise they will be of very little use. •These are the principal observations which occur to me on this important subject; and I trust I shall not be accused of presumption when I venture to express my belief, that the certainty of final success in accomplishing the various operations here described, and the practicability of frequently repeating them, if necessary, without endangering an opacity of the cornea, or any other irremediable disease of the eye, will render this Treatise an acquisition in the Ophthalmic branch of Surgery. I now present it to the notice of the Public, with a fervent hope, that by the general adoption of the practice which it recommends, many an unhappy sufferer, who hitherto has been doomed to continue in darkness, will be restored to the inestimable blessing of sight.

CASE V.

SUSANNAH GOBY, of Spesbury, near Blandford, ætat. 30, labouring under closed pupil, was recommended as an in-patient to the West-of-England Infirmary for curing diseases of the Eye, March 1810, by Sir Thomas Acland, Baronet, one of the Committee of that establishment. She stated, that seven years before, from exposure to cold, a violent inflammation came on in both eyes; which, though lessened by surgical aid, could not be entirely removed for six or eight months, when her vision became so much impaired, that she could only see large objects, and even those very imperfectly. At the termination of five years from this period, she underwent an operation on each eye, in the Salisbury Hospital; but of what nature I could not clearly understand, for though she stated, that a fellow-patient told her there had been a film like a cobweb taken out of each eye, yet, on the most accurate inspection, I could not perceive any appearance of a cicatrix in either cornea. The eyes were considerably smaller than the natural size, and very soft to the touch, apparently from a dissolved state, and a

deficient quantity of the vitreous humour. The iris in both had assumed a greenish hue, and the pupils were contracted to the size of a small pin's head. She could discern light from darkness, and perceived the motion of bodies when passed immediately before her. As the left eye was not so much reduced in size as the right, I conceived it would afford the greatest chance of success to the operation, and accordingly, on the 8th of April, I proceeded, in the presence of my late colleague, Mr. C. T. Johnston, to make a central division of the iris, the radiated fibres of which instantly retracted, and formed a pupil of a large size. I next endeavoured to separate the capsule from its adhesions to the posterior part of the iris; but not finding this readily accomplished, and dreading the escape of the disorganised vitreous humour, I desisted at the time from any further attempts. The iris having been much stretched by these efforts, she complained of a slight pain during the operation; but no inflammation ensued. April 15th, with a needle curved somewhat less at the point than Scarpa's, I detached, and afterwards pushed the capsule in a mass through the newly-formed pupil into the anterior chamber.

The patient experienced considerable pain, and in the course of the day inflammation came on. This however yielded to the application of six leeches to the eye-lids, and at the expiration of a week, the eye was as free from redness as previous to the operation.

At this period I was called to Bath, in order to operate on several cases of cataract; in which city, by permission of the Committee, I remained for a considerable time. Mr. Johnston, however, informed me, that during the first month, the capsule rapidly diminished in bulk, but that no material alteration was observable in the subsequent three or four weeks. On my return I found the pupil nearly circular, and considerably larger than the natural size; but, except a small part towards the internal canthus, it was still obscured by the remainder of the capsule, which had, however, become much thinner, semi-transparent, and full of small holes. By the assistance of cataract spectacles, she could see to read small print. Being confident of the ultimate disappearance of the capsule, and the bed she occupied being much wanted, this patient was discharged, July 1st, 1810.

In the beginning of January, 1812, the friends of a young lady, whose eyes were affected in a similar manner, at my request wrote to Dr. Heywood, a physician of eminence residing at Blandford, to inquire the state of Susannah Goby's eye at this period, who returned for answer, that the remainder of the capsule had nearly but not entirely disappeared; "that her vision was much better than could have been expected before the operation, for which she felt very grateful."

CASE VI.

During my stay in Dublin, in 1811, my assistance was solicited in behalf of Henry Ledwith, a pauper who had been a coachman in that city, aged 46. This poor man was affected with a cataract in his left eye, while the pupil of the right had become nearly obliterated in consequence of the extraction of the opaque crystalline, thirteen years before. The upper edge of the pupil in the latter eye was dragged down, below the opacity in the cornea, caused by the former operation. He

could discern light and colours, but could not distinguish the largest objects. I performed the operation for closed pupil, on the 25th of June, in the presence of my highly respected friend Mr. Stewart, the Surgeon General, and most of the eminent Surgeons in Dublin. I succeeded in making a central division of the fibres of the iris, two thirds the extent of its diameter, excepting one spot in the centre, which remaining entire, and the original pupil being enlarged, owing to the retraction of the iris upwards, three distinct openings were formed, each large enough to admit of accurate vision. There was no capsule, and the patient was enabled immediately after the operation to see minute objects. When the bandages were removed at the end of eight days, he saw to read distinctly with the assistance of convex glasses. It may here be proper to remark, that this patient did not experience that confusion of vision, which might *a priori* have been expected, though many objects appeared to him doubled. July 22d, I operated a second time on this eye, and cut through the remaining parts of the iris, which separated the three apertures; thus forming them into one large pupil, nearly circular,

and more than three times the natural size. He now no longer perceived objects double, and saw much more distinctly than before. At the time of performing the first operation on the right eye, I endeavoured with a double-edged needle to cut in pieces the cataract in the left; but being very hard, the capsule immediately separated from its ciliary attachment, and as the vitreous humour did not afford sufficient resistance to enable me to accomplish the division, I endeavoured to depress it out of the axis of vision.—It however again returned to its natural situation. Some time after this, at the request of the patient, I performed the operation of extraction; but the moment I had completed the section of the cornea, the opaque crystalline escaped through it with considerable force, and was followed by the greater part of the vitreous humour, which was perfectly fluid. So considerable an inflammation ensued from the protrusion of the iris, that notwithstanding he was copiously bled, the eye suppurated, and was lost. As the eye was of its natural size and hardness previous to this operation I had no reason to suspect that the vitreous humour had undergone such a morbid change.

CASE VII.

The Reverend Doctor Jessop, of Mount Jessop, County Longford, Ireland, ætat. 70, consulted me, during my stay in Dublin, in 1811, respecting an affection of his eyes, by which he had been for a long time deprived of sight. Besides labouring under cataract, complicated with gutta serena, in his right eye, which necessarily rendered every attempt to afford relief by an operation hopeless, the pupil of the left eye had become closed, subsequent to the extraction of the lens, by the Baron De Wenzel, more than twenty years before. In addition to this circumstance, full two-thirds of the lower part of the cornea had become opaque in consequence of the above operation. The Doctor informed me that a considerable protrusion of the iris through the section of the cornea followed the extraction of the crystalline, which occasioned great irritation and pain for three months, at the termination of which the tumour disappeared; but he found himself only capable of discerning light and brilliant colours.

Early in July 1811, in presence of that highly respectable surgeon, Mr. Richards, president of the

Royal College of Surgeons, Dublin, I performed on this eye the operation for closed pupil. After dividing the fibres of the iris, opposite to, and co-extensively with the transparent part of the cornea, near its upper margin, without much difficulty, I found the opaque capsule remaining, and very much thickened; this I pushed below the new pupil. The patient complained of no pain during the operation, nor did the least inflammation succeed. For the first four days, his vision did not amend; but afterwards began gradually, and progressively to improve, and in a fortnight, he was able to decypher the seconds marked on a watch dial, small print, &c. In this case, (as well as in several others, after the failure of extraction), I have found the vitreous humour in a dissolved state; for on withdrawing the instrument, so much watery fluid escaped through the puncture it had made, that the coats were nearly drained, and became flaccid, but in less than twenty-four hours the eye had regained its natural hardness. Although the vitreous humour was perfectly disorganised both in this and Case VI, yet the eye-balls having preserved their natural

hardness, it was in neither instance suspected previous to the operation. *

CASE VIII.

Sarah Williams, of Hunsum near Tiverton, Devon, was admitted an out-patient of the West-of-England Eye Infirmary, August 20th, 1810. She stated, that eight months before, the prong of a fork had been thrust by accident into her eye, which pro-

* After these sheets had been sent to the press, I received a letter from Doctor Jessop, in as good hand-writing as could be expected from a gentleman at his advanced period of life, even had his eyes never suffered from disease. In this letter says the Doctor, "I can see to play at whist, and every game at cards, without a mistake, nearly as well as I ever did.—I write all my own letters, and walk about my demesne, at Mount Jessop, with ease and satisfaction, being able to see the house, windows, and door, across the lawn, a distance of a quarter of a mile. The capsule has fallen beneath the pupil, but is not dissolved—the old opacity in De Wenzel's eye is almost quite clear; which, I think, must be owing to the effect of the opiate wine which you recommended me to use. Ledwith, the coachman, (Case VI.) sees as well as you do yourself."

duced a violent inflammation, that continued for several weeks, and terminated in the total loss of vision in that eye. On inspection I found the pupil wholly impervious. Part of the iris, having protruded through the opening made in the cornea by the fork, still adhered to the cicatrix. On the 24th of August, I made a large transverse opening in the centre of the iris, and afterwards, carrying the knife through this aperture into the anterior chamber, separated the adhesion it had contracted to the cornea. The iris instantly receded to its natural situation, and the anterior chamber resumed its original capacity. Some fragments of opaque capsule remained, which having been broken in pieces, were soon absorbed, when the pupil appeared of a larger size than usual, perfectly clear, and nearly circular. The patient did not complain of pain from the operation, nor was there any subsequent inflammation. She was discharged, cured, in three weeks after her admission, and saw as well with that eye as with the other, by the assistance of a convex glass of two inches and a half focus.

CASE IX.

About the beginning of May 1811, when at Bath, I was consulted by James Nash, a carpenter, of Wilton in Wiltshire, who had lost the sight of his left eye. On examination I found the pupil closed, which had been occasioned by a splinter of iron striking his eye nearly five years before, while driving a nail. The splinter had penetrated through the inner part of the cornea close to its junction with the sclerotica, and so much of the iris protruded through this opening, that the natural pupil was dragged under the cicatrix, and not larger than a pin's head. He could see colours and the motion of objects, but nothing farther. I operated on him, May 3d, in presence of my friend Dr. Chicester and several other gentlemen of Bath. I introduced the knife in the usual manner, and made an opening of a large size, through the centre of the iris, and opaque capsule, (the crystalline lens having been absorbed); but the radiated fibres of the iris did not, as is usually the case, immediately retract, though I repeatedly stimulated the iris with the point of my instrument. Some of the detached pieces of

capsule fell into the anterior chamber, but the greater part remained in situ. Next day I removed the dressings to examine the eye, and was surprised to find, that the fibres of the iris had receded, and very much enlarged the newly-formed pupil, which was of a transverse and oblong shape. The fragments of capsule in a flocculent state occupied a large part of the newly-formed pupil, notwithstanding which the patient could read with this eye assisted by a convex glass. No inflammation occurred during any part of the treatment, and within a fortnight from the period of the operation, the fragments of the capsule had entirely disappeared, and he returned home able to see the minutest objects.

CASE X.

JOHN MERCER, Market-row, St. James's, was brought to me the middle of January 1812, by one of my patients recently cured of cataract. He stated that, in May 1809, he was attacked in the night with acute inflammation in both eyes; this in a day or two was succeeded by the appearance of dark

streaks floating before them, which prevented his seeing objects distinctly. Shortly after, he was struck by the tail of a horse, in his left eye, with such violence, that an opening was made in the cornea, through which was protruded a small portion of the iris. Total blindness in this eye was the consequence, and the inflammation in the other not decreasing, he was obliged, in less than a fortnight after the accident, to relinquish his employment as a coachman. He then applied and was admitted as an out-patient to an eye infirmary. Becoming however progressively worse, after four weeks regular attendance, he procured admission into a general hospital, where he remained three months without receiving the slightest benefit, when he applied for his dismission. Unwilling, however, to relinquish all hope, he once more solicited admittance, and was received into another infirmary for curing diseases of the eye, where, in the course of six months, he underwent five operations in the right, and three in the left eye, for contracted or what is usually termed obliterated pupil complicated with cataract. The benefit which he received from these operations, was as great as the nature of the case admitted, without an enlargement of the pupil

by a division of the fibres of the iris. The clear aperture in the right eye was of the size represented in Plate II, Figure 1. In the left eye, though the pupil was larger, nearly round, and perfectly free from all opacity, yet he saw with it very imperfectly, from which I conceived, that the retina was injured by the blow he had received. With the right eye he could at times discern minute objects with distinctness when placed immediately before him; but occasionally when walking, the dark streaks already noticed presented themselves in such a manner as to induce him to stop suddenly, fancying that something which appeared to cross him would impede his further progress. He walked in the streets by day without a guide, but from the smallness of the pupil his sphere of vision was so circumscribed that he could with difficulty avoid objects, unless immediately before him; and on one occasion had been nearly run over by a carriage crossing him at a right angle, which he did not perceive till the pole struck him. At night he never but once ventured abroad without a guide, as he could not see to avoid obstacles however large unless when nearly in contact with them. He was extremely anxious I should perform an operation, "which would enable

him to see sideways," but, as he had been so recently under surgical treatment, I hesitated to comply with his request. Observing my hesitation, he informed me, that since his dismission as an in-patient from the last-mentioned institution, he had repeatedly applied for the purpose, if possible, of obtaining further benefit, but was advised to rest contented, and not to risk the loss of what he had already gained. Under these circumstances, I resolved to operate on the right eye. And on the 2d of January 1812, made a large aperture in the centre of the iris, and formed a pupil transversely oblong. * It was perfectly clear, excepting at the external canthus, which was occupied with a minute portion of opaque capsule. No pain or inflammation succeeded the operation. In a week, the patient could read small print at a moderate distance; but the dark streaks still occcasionally floated before his eyes. These however gradually lessened, and his vision daily improved. In another week he could see his fingers and nails, when his arm was extended to the utmost, at right angles with the body, nearly as

* Vide Plate II. Figure 2.

distinctly as he could before I saw him, when they were placed before his eye.

The poor man expressed to me, in the liveliest terms of gratitude, the confidence and security with which he could then walk through the streets. At the end of three weeks, he told me, he was capable of seeing the earthen pots on the chimnies, trees, &c. half across Hyde Park, and the streaks had very much lessened; I now observed for the first time a small filament of capsule, apparently not larger than a hair, which adhered to the posterior part of the iris, and waved about in the vitreous humour. At first I thought this was the cause of the black streaks before mentioned, which although very much lessened, yet remained to a certain degree; but on further consideration it was evident this opinion was hastily formed, as this was one of the first symptoms under which he laboured when originally attacked with inflammation. He is now able to walk the streets at night as well as by day; and he informed Doctor Warren of Albemarle-Street, to whom I showed this case, that he had seen to tell the exact time by St. James's Church clock across Piccadilly by moon-light, and had repeatedly read writing and small print by the light of a candle,

whereas, before he became my patient, he could not see sufficiently well to feed himself with comfort by that light. He considers his powers of vision more improved after night than even by day.

CASE XI.

Richard Bligh, of Liskeard, Cornwall, aged 33, by trade a shoe-maker, had been in the Navy about six years, from which he obtained his discharge on account of a pulmonic affection, and worked for two years at his former trade. In the year 1803, from exposure to cold while in a state of intoxication, he was attacked with violent inflammation, first in the left eye, and a month afterwards in the right. For this complaint he was attended by a respectable surgeon for five months, whose treatment though judicious was not successful, as at the end of this period, when the inflammation was subdued, his vision was wholly destroyed, and he continued perfectly blind until admitted a patient in the West-of-England Eye Infirmary, 27th of April 1809.—On examining his eyes I found the

right eye sunk within its orbit from preceding suppuration, while the pupil of the left was not larger than the head of the smallest-sized pin, and that aperture was filled up by an opaque substance. The adhesions between the posterior part of the iris and the anterior portion of the capsule were so firm, as wholly to resist the action of the belladonna. He had a faint perception of a strong light, but could not discern even the outlines of objects. On the 30th of April I performed the operation on this patient, in the presence of Mr. Hockin and my late colleague Mr. C. T. Johnson. It was attended, as is usual, with little pain, no blood appeared in the anterior chamber. The lens, which was transparent, and the opaque capsule, were cut in pieces and placed so as to act as a plug to prevent a re-closure of the divided iris. Immediately after the operation the rays of light were admitted through the newly-formed aperture sufficiently to enable him to distinguish objects. He was then ordered home to bed, and to abstain from animal food and fermented liquors. These injunctions he so entirely disregarded that he got drunk the evening of that day, prior to which excess he was easy and perfectly free from pain. The next morning I found he had con-

siderable inflammation, and immediately bled him ad deliquium.—This removed all unpleasant symptoms, and no further medical treatment was required during his cure than gentle aperients. The lens, from its exposure to the aqueous humour, in a few days became opaque. In three weeks the solution and absorption commenced, and proceeded so rapidly as to leave the pupil, which was of a transversely oblong shape, nearly clear ten days after. He could then see minute objects, and in six weeks from the operation was discharged cured. A month after his return home he walked from Cornwall to Exeter, a distance of 60 miles, as conductor to a blind relation, who in consequence of his cure wished also to become an Infirmary patient. After the lens had become absorbed, as an experiment, the belladonna was applied, but had not the least effect in enlarging the size of the pupil. Two years after this, I heard his vision was so much improved that he had resumed his employment as a shoe-maker.

CASE XII.

Catherine Spelman, Kilbeggan, County Westmeath, Ireland, ætat. 31, about five years ago was attacked with inflammation, which ended in closed pupil in her right eye, and an enlargement and complete amaurosis in the left. She applied to me, in Dublin, June 16th 1811, when she could very indistinctly discern colours and the motion of objects with her right eye. I performed the operation by dividing the fibres of the iris in the usual manner, and plugging up the opening by pieces of the cataract, the remainder of which I pushed into the anterior chamber. She had considerable inflammation after the operation, which was removed by bleeding, purgatives, &c. The absorption went on so rapidly that in five weeks the newly-formed pupil appeared pefectly clear, when she could see the smallest objects. The pupil was about a line in width, and extended very nearly across the whole extent of the diameter of the iris. When the minutes of this case were taken down, the patient was examined by Doctor Hartegan, the eminent professor of anatomy, Trinity College, Dublin, in whose presence,

assisted by cataract spectacles, she threaded a small needle with great ease.

CASE XIII.

John Curtis, from Lancells in Cornwall, ætat. 23, was admitted an out-patient of the West-of-England Infirmary for diseases of the eye, July 1810. For two years he had had inflammation in both eyes, which resisted every means employed to arrest its progress, and at last terminated spontaneously, leaving him quite blind. I found one eye so much diseased as to afford no chance of relief. The pupil in the other was not larger than a pin's head, and the capsule, which was opake, filled up this small opening. He saw light, colours, and the motion of objects indistinctly when passed before this eye, but could not walk without a guide:—a few days after his admission, he underwent the operation for obliterated pupil. The transverse opening I made in the iris was not of so large a size as I afterwards found necessary, but it was filled up by pieces of the cataract. No inflammation succeeded the operation, and for

three weeks he went on well; when, from exposure to cold out of doors, such violent inflammation supervened as required bleeding, leeches and blisters to remove. During this interval, a period of six weeks, the artificial pupil had contracted so much in size as to induce me to repeat the operation. I then succeeded in removing the remaining portions of cataract and effecting a considerable enlargement of the opening; a small quantity of blood became effused in the anterior chamber, and a slight inflammation ensued, which was quickly removed by the application of a few leeches. He was discharged perfectly cured, fifteen weeks from his admission. At this time the extravasated blood in the anterior chamber had disappeared. Some opacity also of the cornea, which existed when he first applied as a patient, was nearly gone. By the aid of cataract glasses he could distinctly see any object, letters, and even the minute and second marks on the dial of a watch, while his vision continued daily to improve.

CASE XIV.

Colonel V—, about twenty-seven years since, was attacked in the Island of Jamaica with an acute

inflammation in the left eye, which terminated in a complete closure of the pupil. Having obtained leave to return to England, he consulted the late Mr. Pott and the Baron De Wenzel, who concurred in opinion that the retina was the seat of disease, and advised the use of electricity. As might be expected, no benefit resulted from its application. He remained in a state of nearly total blindness in this eye, (being able only to distinguish light and brilliant colours) till the beginning of June 1811, a few days previous to which period he consulted me in Dublin. I found the pupil of the left eye not larger than a pin's head, and this small aperture filled by opaque capsule, which firmly adhered to the posterior part of the iris. From the length of time the disease had existed, and the many eminent surgeons and oculists who had pronounced the case incurable, I had great difficulty in persuading him to submit to any operation on it. However, he at length consented to undergo that for artificial pupil, the same day that I operated on a dark-coloured cataract, which four or five years before had formed in his right eye. The 1st of June, in presence of most of the respectable surgeons in Dublin, I cut up the anterior part of the cataract in the right eye very freely,—the fragments

of which fell into the anterior chamber. Some inflammation ensued a few hours after the operation, which was removed by the usual treatment. At the same time I performed the operation for a central artificial pupil in the left eye, and made the transverse incision full two-thirds of the diameter of the iris. I found the capsule most inordinately thickened and adherent throughout its whole extent to the posterior surface of the iris. With some difficulty I cut it in two; but, notwithstanding repeated and long-continued attempts, could not succeed in detaching it. A small part of the nucleus of the lens still remained within the capsule, which on being divided fell into the anterior chamber. A few drops of blood from the divided vessels of the iris rendered the aqueous humour somewhat turbid. I stimulated the iris with the point of my knife, for the purpose of getting the radiated fibres to contract; but for so many years having remained motionless, they were then very little sensible to its action. In ten days, however, they had contracted so much as to pull open the pupil nearly half a line in breadth; a week afterwards, the blood having become absorbed, the patient was enabled to mark the time on a watch-dial, and with the assistance of glasses

could read the smallest print. A fortnight after inflammation came on in this eye without any assignable cause, which assumed an intermittent character, and was ultimately removed by large doses of bark administered by day, and a calomel pill at night. An adventitious membrane was formed during the continuance of the inflammation, which occupied a large part of the centre of the artificial pupil, and partly obstructed the passage of the rays of light; nevertheless he could read and write with this eye. I resolved however to repeat the operation, and not only to remove the obstructing membrane, but also further to enlarge the pupil by detaching the adherent capsule from the iris. These objects, the beginning of August, I perfectly accomplished,—but it was attended with considerable difficulty to myself, and pain to the patient: no inflammation ensued. For some time previous to this the pieces of cataract which had fallen into the anterior chamber of the right eye were absorbed, but the pupil was still obscured by the remaining part. As I thought it of that description which would speedily dissolve by a second operation, after loosening its texture considerably, I pushed it into the anterior chamber; but its solution was so slow, in

consequence of the nucleus not having been divided, that it mechanically irritated the iris, and kept up inflammation in the eye for a considerable time, although so much diminished in size as to leave the pupil clear, which enabled him long before I quitted Ireland to see perfectly with this eye by the assistance of glasses. In this case it was my intention to have made a puncture in the cornea, for the purpose of extracting the remaining small portion of nucleus which kept up the irritation, and it was once actually determined on; but I found my patient could not keep his eye sufficiently steady without the application of the speculum, which very probably would have caused a considerable protrusion of the iris. I therefore suffered it to remain, knowing it would soon become absorbed. When I last examined the eye, the nucleus had diminished to the size of a flax seed, since which period I have not heard of my patient.

CASE XV.

Mrs. S——, an elderly lady, No. 32, Great Winchester-street, Broad-street, City, about twenty-four years since was affected with repeated attacks of deep-

seated inflammation, which ended in depriving her of vision in both eyes, notwithstanding the best professional advice was obtained. She consulted me April 1811, and stated she had been totally blind fifteen years in the right eye, and nine years in the left; that it was the opinion of tlfe different oculists under whose care she had been during the period she suffered from inflammation, that the retina was the seat of disease, and the case therefore hopeless. She had applied to Mr. Saunders a short time previous to his death, whose opinion was also unfavourable, and who discouraged her from undergoing any operation. On examination I found the right eye considerably enlarged, with black protuberances in different parts like small staphylomas; the pupil closed, crystalline lens opaque, and the retina totally insensible.—Nothing therefore could be done to this eye.—In the left the pupil was closed and the lens opaque: she could perceive light and brilliant colours, but the general appearance of the eye was so unfavourable, that I then declined performing any operation, and on my return to London last December would not undertake that for closed pupil, unless the trial was sanctioned by the opinion of some surgeon of eminence. My late anatomical teacher, Mr.

Astley Cooper, was consulted, who advised the operation, which I accordingly performed a few days afterwards. I introduced the artificial pupil knife in the usual manner, and made a very large division of the iris in the line of its central diameter.—Having separated all connexion between the opaque capsule and the posterior part of the iris, I found that some of the fibres were broken off at the same time; these afterwards became absorbed, and left the artificial pupil of a very large size.—The vitreous humour did not afford a sufficient counter-resistance to enable me to divide the thickened capsule; I therefore postponed any further attempt to accomplish this object, although it occupied the whole extent of the opening behind the iris. During the operation my patient suffered little pain; but as in the evening she felt some uneasiness, I ordered her to be bled, which, with the repeated exhibition of small doses of tinctura digitalis, in a few days arrested the progress of all inflammatory action. The opaque lens with its thickened capsule, which were of an unusually large size, in less than a fortnight had spontaneously sunk in the vitreous humour, and left a small portion of the upper part of the pupil clear, which enabled her to discern

objects. In five weeks the half of the pupil was clear, and with the assistance of convex glasses she could read the smallest print.

The beginning of April, 1812, when the latter part of this case was noted down, the opaque lens having sunk beneath the lower edge of the pupil—the whole extent of the artificial opening was clear while the eye remained steady; but on moving it quickly, the cataract floated about in the vitreous humour in a most extraordinary manner, seeming occasionally, when the eye was moved for a moment, to obscure the whole pupil, but as soon as the eye again became stationary (if sitting erect), it instantly sunk below the axis of vision.

This opaque body appeared not the least diminished in size: but, as she was able to read small print for several hours together, without inconvenience, and even to thread a small needle, I did not judge it advisable to attempt a division of the capsule, for the purpose of effecting its absorption.—The very large size of the artificial pupil is here of the greatest advantage; for had it been smaller, vision would necessarily have been completely obscured, during the floating of the cataract, as often as it rose above the transverse diameter of the iris; whereas she is not sensible

of any obstacle, unless when the head is held forward. The strongest sun-shine is not distressing, as the eye-lids involuntarily become in part closed, and shut out the superfluous rays of light. This fact I have uniformly remarked where the artificial pupil has been of a very large size. The vitreous humour, I should conceive, is wholly disorganized, from the spontaneous depression of the cataract, and its floating up and down so readily. The most extraordinary circumstances in this case are, the gradual sinking of the cataract, and that it has never appeared either to float towards the back part of the eye, or to sink below its usual seat.—In general its convex surface is towards the iris; but it sometimes appears to roll when it moves in the eye.

CASE XVI.

While I was in Dublin, a poor man, who had been a patient in the London Infirmary for curing diseases of the eye, consulted me on account of a considerable enlargement in his right eye, and very indistinct vision in the left.—He suffered great pain in his forehead and cheek from pressure caused by the

enlarged eye, and rather more than the inner half of the cornea of the other was obscured by a dense cicatrix. There had been a considerable protrusion of the iris through an ulcerated opening in its cornea, and the pupil, which was partly obscured by the cicatrix, was very small. When discharged from the Infirmary, Mr. Saunders had given him some of the extract of belladonna, which he applied constantly for two years, and during that period it had produced its specific effect of enlarging the pupil, thereby affording useful vision. Some time previous to my seeing him, he had discontinued the use of the belladonna, as it ceased to produce any effect. I however tried it again, when it acted as powerfully as before. I first performed the operation of excision of the cornea on the enlarged eye, by which the humours escaped, the eye lessened, and sunk within its orbit, when all pain in the forehead and cheek ceased. A short time before I left Dublin, assisted by my nephew Mr. Hockin, I performed the operation for lateral pupil in the left eye, by dividing the iris very nearly from the junction of the sclerotic coat to the edge of the opacity in the cornea, and then freely cut in pieces the crystalline lens and its capsule, which were both transparent. I placed a

part of these in the anterior chamber, the remainder I used as a plug to prevent the incision in the iris from again uniting. The man immediately exclaimed that he could see objects more distinctly than before; but in two or three days the divided portions of the lens becoming consequently opaque, this increase of vision was for some time lost. Some inflammation ensuing, he was bled; which, with warm applications, &c. soon relieved him. Soon after the operation I quitted Dublin for England; prior to which the divided lens had assumed a flocculent appearance, but his vision had not much improved. My nephew, however, who remained some time after my departure, informed me, that when he left Dublin, although the artificial pupil, which was of a large size, was still much obstructed by the remaining parts of the lens, yet his vision was considerably better than when I first saw him. I have not since heard of him; but from the large size of the opening made in the iris, and the certainty of the remainder of the cataract becoming absorbed, there can be no doubt but this case has terminated in the manner I wished and expected.

CASE XVII.

William Dangerfield, a soldier, was one of the unfortunate sufferers from the Egyptian ophthalmia, which had left indelible opacities in the central parts of the corneæ. During the acute stage of the disease, the iris had protruded so much in both eyes as to obliterate the pupil in each, a very small portion only of the cornea remaining clear round its juncture with the sclerotic coat.—The patient could only distinguish light and colours. Four days after his admission as an out-patient of the Exeter Eye Infirmary, he underwent the operation for artificial pupil in his left eye. I introduced the knife at the upper part of the eye above the level of the pupil, to prevent the escape of the aqueous humour, and with one cut of the instrument divided the whole of the iris opposite to the remaining clear part of the cornea. The newly-formed pupil was consequently perpendicular, instead of being transverse. No inflammation ensued.—A fortnight after, I operated on the right eye, and succeeded in dividing the iris in a similar manner; but here there was a good deal of subsequent inflammation, which re-

quired bleeding, poultices, &c. to subdue. A chronic species of ophthalmia remained for nearly six weeks, which kept up an irritation in the eye, but at the end of that period the lens had wasted so much as to leave the newly-formed pupil nearly clear.—The absorption of the lens in the left eye not proceeding so rapidly as I wished, I introduced a cataract needle, and cut it into small pieces, the greater part of these I pushed into the anterior chamber. Some inflammation succeeded, but was soon removed by the application of a few leeches, and at his own request he was discharged the beginning of October, before the whole of the lens was entirely absorbed in either eye. The opening in the iris of each eye was of a large size; but from their lateral situation, he was consequently obliged to look at objects obliquely. He could find his way without the assistance of a guide, and by the help of suitable convex glasses could see small objects with tolerable distinctness—but his sight was certainly very inferior to that which commonly results from the central artificial pupil.

CASE XVIII.

Early in the summer of 1811, the child of a soldier belonging to the 7th Hussars was placed under my care, at the request of Colonel Vivian, who commanded the regiment at that time quartered in Dublin. Soon after its birth, from the purulent ophthalmia the cornea of the right eye had become ulcerated through its whole substance, and a slight protrusion of the iris ensued. An adhesion of the edge of the pupil to the cicatrix, consequent to its healing, had so much lessened its size that it was completely obscured behind the cicatrix, and the patient could merely see the motion of objects, light, colours, &c. Under these circumstances, having seated the child in the usual manner as for performing the operation for cataract, I introduced the artificial pupil knife into the cornea about a line anterior to the iris, and liberated the adherent edge of the pupil; I afterwards brought a part of the iris through the opening made in the cornea, by which the natural pupil was dragged opposite to the remaining clear part of that coat. Both these objects I accomplished with facility; the iris, from the pressure

of the speculum, immediately after its liberation, protruded through the puncture in the cornea so much as to bring its pupillary margin in contact with the cut.

No inflammation succeeded the operation, and in a few days a weak solution of argentum nitratum was dropped into the eye two or three times a day, which assisted to heal the puncture, and entirely removed the projecting part of the iris. At the end of six weeks, the child could discern small objects both near and at a moderate distance with a precision surpassing my expectations, and which promised a vision sufficient to answer all the common purposes of life.

CHAP. III.

SECTION I.

ON CATARACT.

THE disease of cataract, which is the subject of the present chapter, has been so often and so ably treated of by various authors, that I shall in this as in the two former, confine myself as much as possible to the recital of the various facts and observations which have occurred to me in the course of my practice, and only add what is necessary to their elucidation. For the sake of clearness, however, it is to be recollected that the morbid affection termed cataract, consists of an opacity of the crystalline lens or its capsule, and sometimes of both; when the opacity is seated in the former, it is called lenticular cataract; when in the latter, membranous or capsular cataract.

The formation of the cataract is generally slow in its progress, though this is not invariably the case; neither is its aspect uniformly the same. The pupil at first usually assumes a turbid and muddy appearance, which increases until it becomes entirely opaque. It is observed to be of every shade from a milky whiteness to the palest blue, and sometimes so nearly approaching to the colour of the natural pupil, as to have deceived the most experienced oculists. The lens and capsule are both frequently found to be opaque; at other times the opacity is confined to the capsule. The seat of disease may be either the anterior or posterior part of this membrane, or both these parts may be equally affected. Authors have divided cataracts into several kinds, according to their different degrees of solidity, and the seat of the malady.

Neither age nor sex seems to be exempt from this disease; children are frequently born with it. In adults it sometimes arises in consequence of external violence, or inflammation of the eye, and in these cases it may be regarded as altogether a local disease. Frequently, however, it proceeds from an hereditary disposition, which has existed for several successive generations, while in other cases it attacks several

members of the same family, without any disposition of this kind being recognizable in their progenitors. Facts illustrative of these positions are recorded by different authors. Among others, Janin mentions a whole family of six persons who laboured under this disease.* Richter extracted the cataract from a patient, whose father and grandfather had been affected with the same malady, and in whose son, at that period, it had begun to manifest itself. He adds, that he had seen three children all born of the same parents, who acquired cataracts at the age of three years.† During my apprenticeship with the late Mr. Hill, of Barnstaple, I was present, when he operated on two brothers and a sister, all of whom were adults, and who stated that three or four others of their family were affected with symptoms not unlike those they had experienced at the commencement of the complaint. I myself recently operated on two gentlemen advanced in years, who informed me, that they had a brother, on his return from India, who was similarly affected.

---

* Observations sur l'Œil, p. 149.

† Richter on the Different Kinds of Cataract, p. 3.

Cataract is not the only disease of the eye, with which whole families are attacked. Mr. Lucas, surgeon of the Leeds Infirmary, mentions, in a paper published in the Medical Observations and Inquiries, Vol. VI. that he had seen a part of a family of five children who were born blind, and from his statement it appears that cataract was not the cause of this blindness. During my residence at Exeter, a poor man brought me two of six children, all born blind from amaurosis; and I have seen part of a family, of several brothers and sisters, all of whom laboured under hemeralopia.

Congenital cataract, like that in adults, consists of an opacity either of the lens, of the capsule,—or of both. The lens affected with this disease is either solid, soft, or fluid; and it is sometimes partially, sometimes wholly absorbed; in the latter case the cataract is termed membranous or capsular. The origin of congenital cataract is necessarily involved in much obscurity, and in many instances, it cannot be traced to any assignable cause: in other cases, however, as in advanced life, it appears successively in several members of the same family, and is also transmitted from parent to child. While in Dublin, I operated on one of seven children, five

of whom had congenital cataract, and whose father and grandfather, according to the mother's statement, were both born blind with the same complaint. About the same period I successfully operated for congenital cataract on two children of a Welch harper, of the name of Lewis, who himself was born blind of that disease. He indeed affirmed they were not blind at the time of their birth; however, from the involuntary motion of their eyes, and their complete ignorance of all visual objects, after the removal of the cataracts, I have no doubt, the cases were both congenital. Though this imperfection in the organs of vision may readily escape observation in early infancy, yet I conceive I have not unfrequently observed an unwillingness on the part of parents to admit, that such a defect existed in their offspring at the period of birth. A gentleman consulted me at Exeter, respecting an imperfection in the vision of his son, who had nearly attained his twentieth year. On inspection I discovered, that he laboured under that species of congenital cataract, of a dark slate colour, in the centre, with a transparent edge, which admits a passage for the rays of light sufficient to give an imperfect vision, when the pupil is in an expanded state. As different surgeons

had previously examined the eyes of this patient, without ascertaining the real cause of his malady, it was with some difficulty I could prevail on his father to confide in my opinion. He at length, however, consented that his son should undergo the operation for cataract, which I accordingly performed, and the result was of the most satisfactory nature.

It is somewhat singular, and may perhaps be deemed not unworthy of remark, that in all the cases of congenital cataract, which have fallen under my notice, where more than one child in a family have been affected, it has invariably occurred in succession. For example, in the Russell family, consisting of seven children, the two eldest brothers enjoyed perfect vision, while the five younger daughters laboured under congenital cataract.* Captain P—'s eldest daughter, in like manner enjoyed perfect sight, while his three other children were born blind.† The fact observed by Mr. Saunders is still more remarkable, that the same character was preserved in the cataracts of children belonging to one family,

* Vide Cases 19, 20, 21. † Vide Cases 22, 23, 24.

though in one instance there was a difference of six years, between the ages of two brothers.* Some writers have attributed this peculiar pre-disposition to a strumous diathesis in the parents. I cannot, however, acquiesce in this opinion; for though I have certainly observed a scrophulous disposition in a few patients labouring under congenital cataract, as well as in others, where the lens has become opaque at an advanced age, yet this association is by no means so general, as to warrant any positive conclusion on the subject.

Syphilis may be ranked among the causes of cataract; and I am of opinion, in such cases the opacity is always at first seated in the capsule, though it may afterwards sometimes extend to the lens, and generally arises from an inflammation of that membrane, and not from coagulable lymph having been

---

* In a majority of cases I have myself witnessed the same uniformity of character under similar circumstances, though in other instances, as in the family of Captain P. already mentioned, the eldest of the two daughters laboured under slate-coloured cataracts with a transparent edge, while those of the brother and younger sister were fluid with opaque capsules.

effused from the inflamed vessels of the iris, and deposited on its anterior surface. I was led to adopt this opinion from repeatedly observing, in the commencement of syphilitic inflammation of the iris, that although the pupil was very little contracted, yet the patient had entirely lost the power of discerning objects, and could only distinguish light from darkness. This state of the disease is accompanied merely with a haziness of the capsule, which usually disappears within forty-eight hours after ptyalism has been produced, when vision is again restored to its natural clearness. Had there been any deposition of lymph on that part of the capsule opposite to the pupil, it must have been visible at the previous examinations, and would not have disappeared in so short a time after the action of mercury had shown itself. But what I conceive proves that opacity in the capsule arises from some morbid action in its own vessels, and not from lymph effused by the vessels of the iris, and deposited on the surface, is, that it frequently occurs some months, or even years, after extraction of the cataract has been successfully performed, without any inflammatory action in the iris, and that in congenital cases the

density and thickness of the capsule increase in proportion to the length of time it is suffered to remain. I am also strongly of opinion, that in any case of cataract where mercury is found beneficial, the origin of the disease may be traced to syphilis.

Various remedies, internal as well as external, have been at different times recommended for the cure of cataract; a long enumeration of these is useless, as experience has sufficiently demonstrated their inutility. Mr. Ware, indeed, expresses a sanguine hope, that the application of æther and other stimulant remedies to the eye itself, may in a variety of instances supersede the necessity of any operation. The cases, however, where these applications were used, and which are adduced by him in support of this opinion, have all been produced by external violence. It is therefore much more probable, that the lens had been gradually dissolved, and at length finally absorbed by the free admission of the aqueous humour through a breach or puncture, which is generally found to exist in the capsule under such circumstances, (and which is in fact also the proximate cause of the dis-

ease), than that the cure had been occasioned by the stimulant quality of the remedies employed. These cases, therefore, cannot in my opinion be deemed conclusive.*

The above reasoning is still further strengthened by the well-known facts, that cataracts are not only frequently dissipated, where no external applications whatever have been employed, but that when originating spontaneously they are often cured by an accidental blow on the eye.

This desirable event is more likely to occur from a rupture than a puncture of the capsule, because in general the aperture is larger, and is not so likely to re-unite. Accidents of this nature are sometimes attended with so little pain or inflamma-

---

* Whoever has been in the habit of operating for cataract, by separating its texture for the purpose of effecting absorption, must know that the solution of a solid lens in the aqueous humour takes some time to be accomplished; but when the cataract is fluid, it is generally absorded in a few hours, and sometimes in a few minutes.—It is evident, therefore, that there is no want of activity in the absorbents at any time; hence, these stimulants must be regarded as inefficacious.

tion, that no ill consequences are at first apprehended from them. A short time before leaving Exeter, a countryman applied to me on account of cataract in one of his eyes produced by a flap with a bush, which gave him so little inconvenience at the time, that he took no notice of it. A few days afterwards, however, his wife perceived something white in the pupil, which she forbore to mention, lest it should excite alarm. More than three weeks elapsed, before he discovered, by accidentally shutting his sound eye, that he could not discern objects with the other. On a close examination, I discovered a small rent in the capsule, through which a part of the opaque lens protruded. Having almost immediately left Exeter, I am ignorant whether the pupil became clear, though I should rather apprehend, from the smallness of the opening in the capsule, that this membrane would not dissolve. In another instance, where the capsule was much more extensively ruptured from a similar cause, a large portion of the solid lens had fallen into the anterior chamber. The whole of this lens, as well as the capsule, yielded however to the solvent power of the aqueous humour, and was ultimately absorbed; but amaurosis having been

produced by the blow, the patient reaped no benefit from this circumstance.*

---

* Soon after I settled in Exeter, my advice was solicited by a Clergyman respecting his daughter, who was affected with congenital cataract in both eyes. He had while she was a child consulted the most eminent oculists in London, who all concurred in declining to operate, till she should be of an age to understand the necessity of keeping her eyes steady; recommending in the mean time the use of æther. This I advised him to lay aside, and explained how utterly impossible it was for any external application to remove a solid opaque lens, such as his daughter's; adding that in those cases, where it was supposed to have accomplished a cure, the effect had been produced by the aqueous humour having come into contact with the lens, through an opening or rupture in the capsule. However, he remained uninfluenced by my argument, and, as I afterwards unstood, he even censured me for calling in question an opinion sanctioned by such respectable authority. It was rather an extraordinary coincidence, that the man whose case I have last mentioned should be one of this gentleman's parishioners, and subsequently recommended by him as a patient to the West-of-England Eye Infirmary. With the view of tranquillizing the poor man's mind, and inducing him to wait for the gradual disappearance of the cataract, I gave him, on his return home, which was at the commencement of its absorption, merely some coloured water to use as a collyrium, and at the same time wrote to the Clergyman, intreating that he would carefully watch its progress, in order to convince himself, that it was not to æther, but to the sole agency of the aqueous humour, that the cure in such cases was to be ascribed.

The solvent power of the aqueous humour in dissolving the hardest substances, is strikingly illustrated by Mr. Cline, in one of his lectures, in which he mentions a case where from a violent spasm of the muscles of the eye-ball, after the point of the knife had entered, the transparent cornea, it was broken off, and remained adhering to its inner surface. Mr. Cline examined the eye next day, and found that the point of the knife which had been broken off was become rusty; on the fifth day the aqueous humour was turbid and of a rusty colour. On the tenth day, this muddiness had completely disappeared, and the eye looked well and healthy, the point of the knife having been completely dissolved and removed by absorption. The sight of this patient, who was an old man, was afterwards fully restored by the successful extraction of the lens. In corroboration of this remarkable instance, it may not be here improper to mention, that an eminent surgeon in Dublin had a knife constructed somewhat similar in form to the one he had seen me employ in operating for closed pupil; but in one of his first attempts to use it, it broke, and a considerable part remained in the eye, which, however, produced no inflammation, or ill consequence

whatever to the patient. There can be no doubt but the piece was dissolved, though, from being left behind the iris, its gradual disappearance could not be observed, as in the former instance. From these proofs of the powerful solvent nature of the aqueous humour, as well as by the following extract taken from the annual Report of the West-of-England Infirmary for curing diseases of the eye, * it will be seen how utterly unfounded is the opinion of those practitioners, who assert that whatever influence

---

* Ages of Persons cured, born blind.—1st Year.

1 Seventeen Months old,
5 Between seven and ten Years,
1 Fifteen,
3 Between twenty and twenty-three,
1 At thirty.
—
11

Ages of Persons cured, born blind.—2nd Year.

1 Ten Months old,
5 Between two and seven Years,
8 Between seven and twenty,
4 Between twenty and thirty,
1 At thirty-four.
—
19

Ages of Persons cured of Cataracts, not born with them. 1st Year.

1 Eight Years old,
2 Between twelve and twenty,
5 Between fifty and seventy,
4 Between seventy-one and seventy-four,
1 At seventy-eight,
1 At eighty.
—
14

Ages of Persons cured of Cataracts, not born with them. 2nd Year.

1 At six Years old,
6 Between twelve and twenty,
13 Between twenty and fifty,
10 Between fifty and seventy,
6 Between seventy and eighty.
—
36

this humour may exert over fluid or soft cataracts, it is yet wholly inadequate to the solution of the hard cataracts of adults and old people.* — A longer time indeed, and sometimes a repetition of the operation, will be necessary to accomplish the removal of a lens which is very hard; but these are trifling objections, compared with the uncertainty of depression, or the danger of totally destroying the organ by extraction.

Celsus, in describing the operation for depressing the cataract, and who used an instrument very similar to that employed in modern times, observes that "if it rises again, it must be more cut with the same needle, and divided into several pieces, which, when separate, are both more easily lodged and give less obstruction."† It should seem, from this passage, that he had observed the cataract to be more readily cured after being cut in pieces,

---

* In a conversation I had with the late eminent anatomist Mr. Shelden, a short time before his death, he was at first fully impressed with this opinion, and it was with great difficulty I could convince him to the contrary.

† Grieves's Translation of Celsus, page 405.

though he must have been necessarily ignorant of its solution and absorption, as at that period nothing was known of the absorbent system. Bannister, an English oculist, who wrote in 1622, in like manner observes, that " there are some cataracts which vanish and scatter as soon as the needle is applied to couch them, because they are not hard and solid to bear the needle, which goeth through them, as it were a green cheese, whereof they are commonly called cataractæ lacteæ, because their colour and substance resembleth milk. That the chirurgeon may meet this inconvenience, he must labour to loose it, pressing it with his needle on every side; for by this means I have seen and proved, sometime the grossest part of the cataract to fall away, and come lower, the thinner part to be loosed and consumed, and in the end the party hath recovered his sight."

In later times the solubility of the lens has been proved by the celebrated Pott, not only when it was detached from its investing capsule and depressed to the bottom of the eye, but even while it remained in its seat, provided a free admission were given to the aqueous humour, by an opening made in the capsule. Notwithstanding he held these opinions, and like Mr. Hey and Professor Scarpa has recorded

many cases in which the capsule was ruptured, and the substance of the crystalline lens broken down and dissolved, yet still they all appear to prefer the mode by depression, when the cataract possesses sufficient solidity. Professor Scarpa lays great stress on the certainty of the lens becoming dissolved in the vitreous humour after having been denuded of its capsule, by which he conceives that the objections to this operation on account of its liability to resume its natural position, is obviated. If then the superiority of his method consists in the certainty of the solution of the opaque crystalline in the vitreous humour, however hard and solid, would it not be preferable, in every case, to subject the lens to the action of the aqueous humour in the first instance? by which, if sufficiently divided, it will be dissolved in a much shorter period without incurring any risk of a return.

No circumstance has contributed more to improve that department of surgery which regards the treatment of cataract, than the knowledge of the solvent power of the aqueous humour; since it not only enables us to impart sight to the blind during the tender years of infancy, when extraction is wholly inapplicable, and depression cannot be accomplished

owing to the texture of the cataract, but also to remove the cataract in adults and old persons with greater ease and safety to the patients. Though this quality of the aqueous humour, as already observed, was known before the time of the late Mr. Saunders, yet to him unquestionably belongs the merit of having been the first to extend and apply this principle to the removal not only of congenital, but of every other species of cataract. Before him no surgeon appears to have made congenital cataract the particular subject of their attention, or conceived the idea that it might be removed by means different from those commonly employed in adults. Hence, then, as the great mobility of the eye, the smallness and want of consistence in the parts to be operated upon, and the untractableness of children, rendered the two operations in general use wholly inadmissible at an early age,—the little sufferers were uniformly consigned to blindness, during the first ten or twelve years of their existence. Besides the delay in education thus occasioned, the advantages of an early operation must be apparent, especially in those cases where the blindness is complete; since otherwise the retina, for want of due exercise, becomes unsusceptible to its appro-

priate stimulus, and the rolling motion of the eye is so much confirmed by habit, that in some cases it never can be wholly corrected, and it always continues for a long time independent of the will, even after the opacity has been removed. The exposure of the opaque crystalline to the action of the aqueous humour, by freely lacerating the capsule and loosening the texture, or entirely cutting to pieces the lens, is now generally acknowledged to be the only operation applicable to the condition of infancy: but in adults, many practitioners of eminence still contend for the superior advantages of extraction, or depression; while others, like Mr. Gibson, partly taking advantage of the solvent power of the aqueous humour, have recourse to a method compounded of both. Were we ignorant of the powerful hold which habit has even on the most enlightened minds, it would create surprise that any one should be found to contend for operations exceedingly difficult to be performed, and in which parts essential to vision may be irreparably injured, or the eye itself entirely destroyed by the most expert operator, in preference to one easy of execution, almost uniformly successful, which appears pointed out by nature,

and where she herself so materially aids the cure. When this operation becomes better known, I however flatter myself, that every remaining objection must give way to its superior merit.

The long delay attending Mr. Saunders's promised communication to the Public, tended unquestionably to retard this desirable event. So little indeed was the operation known, that in June 1810, when I invited Mr. Ware with several other professional gentlemen to witness one of my modes of operating, in the case of Mr. Purkis of Chancery-lane, (vide Case 27), he candidly acknowledged to the gentlemen present, and after I left London, to the patient and his friends, whom he frequently visited, to observe the after-treatment and the progress of the cure, that he had never practised or previously seen a similar operation.

On this occasion, Mr. Ware did me the honour to express himself much pleased; and I observe, that both he and his Son have since successfully operated in a similar manner on a considerable number of infants and young persons. Nevertheless, he still continues to prefer the operation of extraction, and to express a decided preference of it, when the

disease attacks adults or aged persons.* He acknowledges, that any dread of injuring the iris is now done away, by the well-known property of the belladonna ; but still he considers the slow progress of amendment, and the necessity which often occurs of frequently repeating the operation, to be objections to its indiscriminate use, which have not yet been wholly overcome in his mind.† The uncommon density of the capsule, in the case of Mr. Purkis, doubtless rendered repeated operations necessary ; but, in general, since I have adopted my present mode of proceeding, I find one operation

---

* It will be seen, in a subsequent part of this Work, that the operation Mr. Ware saw me perform was not the one which I usually pursue in the cure of the hard and solid cataracts of old people; and it may be presumed that his opinions would have more nearly coincided with mine, if he had been better acquainted with the whole of my practice.

† "Observations on Cataract, &c. &c. by James Ware, F.R.S. &c." edition of 1811, p. 367. If I may be permitted, however, to judge from a single instance, the remaining prejudices of this eminent oculist have been since removed : as I have recently been consulted by a gentleman nearly thirty years of age, on one of whose eyes he has successfully performed this operation in a case of solid cataract.

sufficient in young persons; and even in cases of solid cataract in old age, I have seldom had occasion to operate more than twice.

Mr. Gibson states, in a recent publication on artificial pupil, that he has been in the habit of breaking down the lens in infants for the last ten years; but, like Mr. Ware, he observes that when the extraction of a cataract can be performed with facility, he prefers that operation. Where, however, that is inapplicable, he recommends depressing the cataract, when it is sufficiently hard, or extracting it when soft, after having previously ruptured the capsule, and reduced it to a pulpy state. With the view of effecting this latter purpose, he makes an opening with the cornea knife towards the outer angle of the eye, at the usual distance from the sclerotic coat. If there exist any doubt of the free laceration of the anterior part of the capsule, he carries the point of the knife obliquely through the pupil, so as to make a more free division of it. All pressure upon the eye-ball being now discontinued, the curvette is next introduced through the incision in the cornea, and the whole of the pulpy cataract removed by degrees. This removal, he adds, is much facilitated by a gentle pressure with

the convex parts of the instrument towards the vitreous humour. From a very extensive experience in soft cataracts in adults, and in children who had them from their birth, I however may venture to assert, that this operation is perfectly unnecessary; since, when the cataract is sufficiently soft to allow the needle to pass through its nucleus, it may, when broken in pieces, be either partially or altogether pushed with perfect safety into the anterior chamber, where it will in three or four weeks, and frequently in a shorter time, be absorbed. I have seen even a solid cataract, in a patient nearly forty years of age, after its central part had been divided, though it remained apparently unchanged for a fortnight, in a few days after become flocculent, and in less than a month from the operation wholly disappear. There seem to me other objections to Mr. Gibson's operation of opening the cornea, either for extracting the soft cataract, or an adherent capsule. In congenital cataract, where this operation will be found most frequently applicable, the action of the muscles of the eye being for the most part involuntary, render any operation impracticable without the aid of a speculum, which, as

in the case of Miss Russell,* will be often found irreparably to derange the form of the pupil.

The introduction of the hook or iris scissars to extract or cut the adherent capsule without wounding either the cornea or the iris, or occasioning a loss of the vitreous humour, requires a degree of steadiness in the patient and dexterity in the operator, both of which are seldom to be met with.

There are two kinds of case, however, in which this operation of Mr. Gibson's will prove useful, provided the patient possesses a sufficient degree of self-command to keep the eye steady without the aid of a speculum. The first is, where a portion of the capsule is wholly detached from the ciliary processes, and floats about in the vitreous humour in the axis of vision.† The second, where the lens has fallen into the anterior chamber, unbroken; in which case, as will be hereafter stated, the nucleus will produce constant irritation in the eye.‡ (Vide Case 30.)

---

* Vide Case 21.

† Vide Case 35.

‡ Although some opacity may ensue from the puncture of the cornea, it is not here so much to be dreaded as in cases of closed pupil, the natural pupil being so remote from the punctured part, that the patient's vision will not be injured.

The preceding objections may be applied, with equal if not greater force, against the methods recommended by Richter, Wenzel, Ware, and others, for the removal of capsular cataract. In the second ed tion of Mr. Ware's works, published in 1805, he advises "the cornea to be divided in the same manner as if the opaque crystalline alone was to be extracted, to the extent of about nine-sixteenths of the circumference of this tunic. He then introduces a fine-pointed instrument, somewhat smaller in size than a round couching needle, and a little bent towards the point, under the flap of the cornea, with its bent part upwards, until its point be parallel with the aperture of the pupil; the point should then be turned toward the opaque capsule, which is to be punctured by it, in a circular direction, as near to the rim of the pupil as the instrument can be applied without hurting the iris. Sometimes the part included within the punctures may be extracted on the point of the puncturing instrument; but if this cannot be done, it should be taken away by means of a small forceps."—Now it must be evident that the danger here is greatly increased by the repeated introduction of forceps and similar instruments to remove the

capsule, inasmuch as by its close connexion with the tunica arachnoidea, this latter membrane must unavoidably be ruptured, and occasion an extravasation of the vitreous humour, by which means the pupil generally becomes either partially or wholly obliterated, or the eye irrecoverably lost from inflammation.

Mr. Ware himself seems fully sensible of this danger, since, in a note in his translation of Baron De Wenzel, page 250, he observes that "the posterior part of the capsule of the crystalline, lies in such close contact with the membrane that covers the vitreous humour, that he believes it to be utterly impossible to disengage and extract the former, without at the same time involving the latter."

It is unnecessary to enter into a detail of the methods recommended by other writers for the removal of the different kinds of capsular cataract, since they appear not to differ materially from those already specified, and are all liable to the same objections.

Before I enter into a description of my operation for this, and every other species of cataract, I shall make a few remarks on the forms of the different instruments used by the most eminent surgeons,

who practise the operation of couching; and, after pointing out the objections to which they are liable, I shall describe those which I have had constructed, and now use, as they in every respect fully answer the purposes for which they were intended.

SECTION II.

A DESCRIPTION OF INSTRUMENTS—OF THE OPERATIONS FOR THE DIFFERENT SPECIES OF CATARACT—AND OF THE AFTER-TREATMENT.

Though a skilful operator may, doubtless, by his superior manual dexterity supply many deficiencies in the form of his instruments, yet I conceive it to be incumbent on every surgeon, after he has determined on the mode of an operation, to consider attentively whether the form of the instrument generally used is well calculated to accomplish his object, or if it be capable of further improvement. This observation, though applicable to every operation which falls within the province of surgery, applies more especially to those intended to remedy the diseases of an organ of such extreme delicacy as the eye.

The employment of the broad spear-pointed couching needle was productive of so great a degree of inflammation, as often to destroy the eye itself. Mr. Hey, of Leeds, was, I believe, the first English author who, in order to obviate this objection, recom-

mended a smaller-sized needle; but the instrument sold in the shops under the name of this eminent surgeon, is in many respects ill adapted to answer the purpose for which it is intended. From its rounded point and wedge-like form, a considerable degree of force is requisite to introduce it through the coats of the eye, and afterwards to conduct it towards the cataract. This compels the operator, if he uses Pellier's speculum, to employ a degree of counter-resistance which is very painful to the patient, and frequently conduces to subsequent inflammation; while, on the other hand, should the speculum be omitted, it will be difficult to keep the eye sufficiently steady to accomplish the object he has in view. If the cataract is to be divided, this instrument, from cutting only at its point, and quickly becoming blunted, will not readily pass through the substance of the lens (unless it be very soft), and in consequence of repeated and unsuccessful efforts, the capsule will very probably become wholly detached from its ciliary connexion, or the lens will be made to press unequally against the iris—in either case, no resource is left but to depress it. The curved-pointed needle of Professor

Scarpa is well calculated to accomplish his method of depressing the cataract; but it is still less adapted than Mr. Hey's, for dividing the opaque lens. Mr. Saunders, while I was his pupil, latterly used a needle about the size of Mr. Hey's, flattened somewhat further towards the handle, having a spear point, which had a sharp edge, only as far as the shoulder. With this needle I at first operated, but soon found it ill adapted to accomplish my mode of conducting the operation; I therefore laid it aside, and tried the one-edged needle, which Mr. Ware now recommends to be used in operating for congenital cataract. This, however, did not long answer my expectations.

The blade of that which I now employ is eight-tenths of an inch long, the third part of a line in width, nearly flat, having a slight degree of convexity through its whole extent. It is spear-pointed, with both the edges made as sharp as possible, to the extent of four-tenths of an inch. Beyond the cutting edges it gradually thickens, so as to prevent any discharge of the aqueous or vitreous humours: the handle is of the usual length.* The

* Vide Plate III. Fig. 4 and 5.

effect of this instrument is easily understood; it enters the coats of the eye with the most perfect freedom, traverses the posterior chamber without in the least degree displacing the cataract, and cuts it in pieces with great ease, where it is not very hard. Instead of the cutting edge being confined to the mere point, it extends so far back, as to be nearly, if not entirely, equal to the diameter of the cataract; by which, in children and adults, I am frequently enabled, at the first operation, to cut in pieces both the capsule and opaque lens. Its convexity also affords a sufficient degree of strength to prevent it from bending during its passage through the coats of the eye, should they present any considerable resistance; but it cuts so very sharp, that this in general is not to be feared. Some caution, in its use, however, is requisite on the part of the operator; otherwise, as it is an instrument of great power, and traverses the eye with so much facility, it may wound the iris, or its point may be carried too far towards the nose. The curved needle which I prefer for capsular cataract, is much less bent at its point than that recommended by Scarpa, on which account the operator can direct its point with greater ease and

precision, for the purpose of separating minute portions of capsule, when adherent to the iris.*

The knife I use for hard cataracts in old people, is the same as that described for making artificial pupil, only of a smaller size.† The superior sharpness of its edge enables me to cut the hardest cataract, and effectually to remove the anterior part of the capsule, however much thickened it may be. This I could not do with the two-edged needle; and in my attempts to accomplish it with that instrument, the capsule has sometimes become either wholly, or in part, separated from its ciliary attachment, when the cataract floated in the vitreous humour, or unequally pressed against the posterior part of the iris, thereby producing considerable pain and inflammation. The speculum of Pellier is, I believe, very generally used in this operation; but the patient often complains more of the pain caused by it, than by the needle. This appeared to me to arise, from the segments of two spherical bodies nearly of the same magnitude being in contact, by which all pressure is confined to a single point. Sufficient

---

* Vide Plate III. Fig. 3.

† Vide Plate III. Fig. 1 and 2.

controul over the action of the muscles of the eye-ball, can therefore only be obtained by using a degree of compression which gives great pain during the operation, and sometimes produces a contusion of the coats of the eye, which I have seen excite and keep up considerable inflammation for some time. It is therefore evident, Pellier's speculum is not well adapted for the intended purpose. The principle which ought to be kept in view in the construction of an instrument for fixing the eye, where the needle is used, is to divide the necessary pressure on as large a surface as possible, instead of confining it to a single point. To effect this, the bearing part of the speculum should be concave, and accurately adjusted to the convexity of the eye-ball, whereby the assistant or operator has much more command over it, and the ill consequences I have just mentioned are avoided. When a student at St. Thomas's Hospital, about six years since, I caused an instrument of the above description to be made of silver wire, similar to that employed in the construction of Pellier's speculum; but it failed to answer the intended purpose, as the curvature was irregular, and did not correspond with the convexity of the eye; its angles were besides so obtuse, as to

prevent it from being easily inserted underneath the lid. Disappointed in my expectations, I have since had another made of solid metal, which possesses the advantage of a perfectly smooth and regular surface. The bearing part is so formed as to make an equal pressure, on somewhat less than one third of the circular outline of the eye-ball; but as this varies in different patients, the operator should always be provided with two or three instruments of different sizes.*

Operation for Solid Cataract in Children and Adults.

In the earlier periods of my practice, I performed one operation and used one instrument; but experience soon taught me that the degrees of hardness, as well as the different species of cataract, vary so considerably, that it was necessary to use different instruments, and adopt different modes of operating. The various operations I am now about to describe, are equally as applicable to persons in middle age,

* Vide Plate III. Fig. 6. 7.

or in advanced life, as to children or young persons, provided the cataracts are of the same consistency and species. I shall begin with the operation for a solid cataract, or when the disease consists of opaque capsule, and some remaining portions of unabsorbed lens, which frequently occurs in congenital cases.

The pupil being in a dilated state from the application of the extract, or a strong solution, of the belladonna within the eye-lids, about an hour previous to the operation, the patient, when the right eye is to be operated on, must be placed on his back, on a table, with his head raised on a pillow, and the light falling on the eye, over the nose. The operator sits behind, holding the speculum in his left hand. On the contrary, when the left eye is to be subjected to the operation, the patient must be placed on a chair of a convenient height, while the operator sits before him, and the speculum is held by an assistant, who stands behind and supports the head. This description applies to adults; but if a child is the subject of operation, three assistants will be necessary; one to secure the head, another the feet and knees, and a third to make pressure on the chest, and also to pull down the lower eye-lid. If the right eye is to

be operated on, the little patient should be laid on the table, and secured as has been just described: but when the left eye is the subject of surgical treatment, if too young to sit up in a chair, he should be laid on a narrow table, his legs hanging over its edge, and his head held on a pillow by an assistant. The surgeon sits before him, and fixing the eye with the speculum in his left hand, he has in this case also the great advantage of operating with his right, while he is enabled in both to direct the eye-ball as he pleases. This variation of position appears to me highly advantageous; as few, if any, can possess the power of using both hands with equal dexterity.

Having secured the eye by a gentle pressure with the concave speculum, introduced under the upper eye-lid, I enter the two-edged needle through the sclerotic coat, about a line behind the iris, with the flat surface parallel to that membrane. I then carry it cautiously through the posterior chamber, without in the slightest degree interfering with the cataract or its capsule, till the point reaches the temporal margin of the pupil; when I direct it into the anterior chamber, and carry it on to the nasal margin of the pupil, in the line of

the transverse diameter of the crystalline lens. I then turn the edge backwards, and with one stroke of the instrument cut both capsule and cataract in halves. By repeated cuts in different directions I afterwards divide the opaque lens and its capsule in many pieces, and at the same time take particular care to detach as much of the latter as possible from its ciliary connexion. As soon as this is accomplished I turn the instrument in the same direction as when it entered the eye, and with its flat surface bring forward as many of the fragments as is in my power, into the anterior chamber, by which means I frequently leave the upper part of the pupil perfectly free of opacity.* By cutting in pieces the capsule and lens at the same time, not only is capsular cataract generally prevented, but the capsule is also much more easily divided into minute portions, than when its contents have been previously removed. The central division of the capsule and cataract prevents the liability of their becoming too soon detached from the ciliary processes, and revolving on the needle, or slipping undivided into the anterior chamber. In cases of large and

---

* Vide Case 32.

solid cataract, this is very essential to the perfect execution of the operation, as the natural connexion of the capsule with the ciliary processes assists, in conjunction with the vitreous humour, to afford a sufficient counter-resistance to admit of its nucleus being completely divided, which, were that connexion detached, could not be effected but by repeated operations. This plan is of peculiar advantage in those cases of cataract termed *elastic*, where, from the great thickening of the capsule, it is almost impossible by any of the usual operations at once to make an opening sufficiently large to admit the escape of its contents; as, by the degree of pressure downwards, necessary to effect this, the opaque body becomes depressed below the axis of vision, but the moment the pressure of the instrument is withdrawn, it again rises to its natural situation, as if touched by a spring.* In all cases when the fragments of the opaque crystalline are placed in the anterior chamber, their solution and absorption are much more rapid, and less irritation is produced than when they are suffered to remain

---

* Vide Case 27.

behind the iris ; which was Mr. Saunders's practice, before he adopted the anterior operation of Conradi, and the one I myself formerly pursued.

When the anterior chamber is large, I now generally push the whole of the divided cataract through the pupil at the first operation, in which situation it becomes dissolved in about a month or five weeks ; and an extensive experience has convinced me that this practice will be always attended with success, when the cataract admits of its nucleus being cut in pieces.*

Operation for Fluid Cataract.

The instrument, and the primary steps of the operation for the cure of fluid cataract, are precisely the same as those for solid cataract ; but, after carrying on the point of the needle to the nasal edge of the pupil, and making the transverse division of the

---

* Vide Case 41 and 42.

capsule, the instrument should be then withdrawn about half a line, and the capsule, which is generally opaque, should be cut in pieces, and separated as much as possible from its attachment to the ciliary processes. The reason I partly withdraw the needle, is to avoid wounding the pupillary edge of the iris while cutting the capsule in pieces; the opaque fluid which immediately escapes into the anterior chamber on the division of that membrane, rendering the aqueous humour so turbid, as to prevent the point of the instrument from being seen. One operation is generally sufficient to clear the whole ambit of the pupil from opacity; but it sometimes happens, particularly with children, that the patient becomes so restless as not to allow the operation to proceed to the full extent. It will then be necessary, by a second operation at a future period, to remove the remainder of the opaque membrane.* When merely a small aperture is made in the capsule, its fluid contents will become mixed with the aqueous humour and be quickly absorbed. The case is then simply capsular cataract, and will require one of the opera-

* Vide Cases 22 and 24.

tions about to be described for the cure of that species of the disease; as the capsule, very rarely dissolves, if suffered entirely to retain its natural attachment.

Operation for Capsular Cataract.

In cases of capsular cataract I prefer the curved-pointed needle already described, which should be introduced through the sclerotic coat at the usual distance behind the iris, with its convex surface forward, and consequently the point directed towards the bottom of the eye. Having passed it carefully through the posterior chamber to the temporal margin of the pupil, (previously dilated by the application of belladonna), I bring it forward into the anterior chamber, and carry it as near to the nasal ciliary attachment of the capsule as I can without a risk of injuring the edge of the pupil. The capsule should then be freely lacerated, and detached

as much as possible round its circumference from the zona ciliaris, when the pieces will soon disappear, provided the capsule is not very much diseased.* Should this, however, be so preternaturally dense as to prevent its free laceration, the needle, after it is brought nearly to the nasal edge of the pupil, as already described, should be carried in the arc of a circle from the internal to the external angle of the eye, by which the thickened capsule will be completely separated from its ciliary connexion, except a small part near the external canthus; or the instrument should be directed from above downwards, by which a similar attachment will be preserved at the lower part of the zona ciliaris. In the former case, I allow the capsule to remain on one side of the iris; in the latter, I push it below the pupil. In either situation it gradually contracts into so small a compass, that it cannot impede the passage of the rays of light even when the pupil is in its most dilated state; while it is prevented from floating in the vitreous humour by the small

---

* Vide Case 29.

remaining attachment to the zona ciliaris. The separation of this attachment must therefore be studiously avoided, as by it the capsule remains fixed; and should it even continue undissolved, the pupil cannot be again obstructed.*

Operation for Adherent Capsular Cataract.

If the capsule should adhere to the posterior part of the iris, in part, or through its whole extent, the same steps should be pursued as where no such adhesions exist, taking care however not to use much force with the instrument; as, should the attachment be very firm, the iris might otherwise be in part torn from the ciliary ligament. By gentle repeated efforts the desired object may be safely accomplished; and I have repeatedly seen the radiated fibres contract, as soon as the adherent membrane was liberated, when the pupil has been immediately restored to its natural size and functions.†

The free laceration or detachment of the capsule

---

* Vide Case 28. † Case 30.

from the ciliary zone through the whole extent of its circumference (excepting the small part to prevent its floating), I consider of the utmost importance; for where any considerable portion of the opaque capsule is suffered to remain behind the iris undetached, the sphere of vision must at all times be very much limited, and in a faint light, or during the night, the dilatation of the pupil can be of no use whatever, the opaque membrane totally impeding the passage of light. The effect of a small aperture in the centre of the capsule, must be nearly the same as that of a fixed contracted pupil. The patient is enabled by day to see objects directly before him, but at night enjoys very imperfect vision, and even by day, the lateral rays of light cannot enter sufficiently for him to see sideways.* I am supported in this practice of freely lacerating the capsule, by the opinions of Professor Scarpa,† who lays great stress on "lacerating the capsule, as much as possible in every part of its circumference, so as to clear the whole ambit of the pupil." He,

* Vide Cases 10, 38.

† Vide his Practical Observations on Diseases of the Eye, page 385.

however, adds, that he afterwards pushes it with the point of the needle into the anterior chamber of the aqueous humour. To this last step of the operation I have strong objections, unless it be first broken into pieces; since it is highly probable, when the capsule is preternaturally dense, that it may remain a long time undissolved, and occasionally produce inflammation by its mechanical friction against the iris.* I have myself known it continue unabsorbed for more than two years after being placed in the anterior chamber without division.† I think it necessary, however, distinctly to state that it is only in capsular cataract, (unless when the vitreous humour is diseased,) that I conceive it expedient to put the opaque body out of the axis of vision; as in all cases of lenticular cataract, where the vitreous humour was sound, I have seen it, when depressed, at some period return to its original situation.‡

Several instances have however occurred to me

---

* Vide Case 31. † Vide Cases 5, 25.

‡ Richter mentions a case where it returned two years after it had been depressed.

where, from the unexpected fluidity of that humour, the cataract with its capsule had no sooner been cut in pieces, than the fragments have spontaneously disappeared, and the pupil become instantly clear.* Where this happens, no danger of the lens again returning is to be apprehended, its specific gravity being greater than that of the disorganized vitreous humour; and having been freely broken in pieces, it no doubt soon dissolves. This state of the eye is mentioned by most of the eminent authors who have written on cataract; and it is obviously one in which extraction must always fail, as, the capsule of the vitreous humour being disorganized, the whole contents of the eye-ball will escape through the section of the cornea, when the eye is irrecoverably lost.

Operation for Solid Cataract in Old Persons.

In old-age, when the nucleus of the lens is frequently so dense and hard that the needle cannot be passed directly through its centre; with a knife

* Vide Case 34.

of the same form as that used for artificial pupil, but somewhat smaller in size, I slice off, by repeated cuts, as much as I can of the opaque crystalline and its capsule, taking care not to dislocate the former body, nor to separate the latter from the ciliary processes. The fragments being then placed in the anterior chamber, leaves a space between the remaining anterior part of the cataract and the posterior part of the iris, which becomes occupied by aqueous humour. This not only acts on, and softens the remainder of the solid lens, but also materially tends to prevent it from pressing against the iris so as to excite inflammation, which, from being deprived of the support of the anterior part of the capsule, it would be otherwise likely to do. If the nucleus of the cataract be not very hard, nor of an unusually large size, when the portions placed in the anterior chamber are absorbed, it may then by a second operation be wholly cut in pieces, and brought forward for the purpose of effecting a more speedy absorption.* Should the surgeon, however, on trial find, from its size and solidity, that he is unable

---

* Vide Case 40.

to accomplish this, he should again slice off as much as is in his power of the softened cataract, and in a similar manner place the fragments in the anterior chamber; when there is no doubt that, by a third operation, the nucleus will admit of being cut in pieces, and placed in the anterior chamber, where it will soon be absorbed. A long time must not be permitted to elapse between the operations, as the circumference of the lens being much softer than the centre, it will first become dissolved; when the nucleus, from its diminished size, may slip undivided into the anterior chamber, where by its mechanical friction against the iris it will keep up a distressing degree of pain and irritation in the eye. This ought therefore to be avoided, by repeating the operations in a proper time. If, however, this accident should occur, I would recommend that a small puncture be made in the cornea, for the purpose of extracting it; for although in most instances it would ultimately become dissolved without producing any ill consequences to the organ, yet by thus removing it, the patient will be saved a great deal of anxiety and suffering.

Operation for Adherent Lenticular Cataract.

Adherent cataract is distinguished by an irregularity in the form, and a greater or smaller diminution in the size of the pupil. From the firm adhesions which exist between the iris and the capsule of the lens, the pupil is fixed; its expansive power being entirely lost, even after the application of the belladonna. In cases where the contraction is great, it will not be sufficient to remove the opaque lens and its capsule, but the fibres of the iris must be divided in the manner described in the Chapter on contracted or obliterated pupil, otherwise, vision will be imperfect and its extent much limited. Should the adhesions be formed before the pupil is much contracted, the whole of the anterior part of the opaque capsule and lens must be cut in pieces and pushed into the anterior chamber, with the small one-edged knife, introduced at a proper distance behind the iris. The extent of the pupil being limited, the surgeon should be very cautious not to wound this membrane with the point of the knife. It will be better to repeat the operation two or three times, than to risk injuring or detaching any part of the iris from the ciliary ligament, which might be

the consequence were any violent efforts made at once to perfect the operation.

Operation for Capsular Opacity with a transparent lens.

From syphilitic inflammation, and from other causes, the capsule frequently becomes opaque, thereby producing partial or total blindness, while the crystalline lens continues perfectly transparent and free from disease. The opacity may be confined either to the anterior or to the posterior part of the capsule; or it may extend to both. When the opacity is in the anterior part of the membrane (which it usually is in cases of syphilis), it is easily discernible; and it generally exists with an adhesion to the iris; but if the posterior part alone of the capsule is the seat of disease, it is with more difficulty ascertained, and it will often require a strong light to fall on the eye, after the pupil has been previously dilated by the belladonna, before its exact situation and extent can be seen. The attendant symptoms are similar to those usually observed in cataract. The pupil possesses its natural sensibility to light,

and the patient can distinguish colours and the outlines of objects. The operation is to be performed with the double-edged needle, in the manner described for solid cataract in children and adults. As the lens is in a healthy state, there will be no difficulty in dividing its nucleus and capsule; after which, without any danger of exciting inflammation, the whole may be placed in the anterior chamber if it is sufficiently large to contain them. I am induced thus particularly to point out the latter species of the disease, because, as far as I have been able to learn, it has not been specifically noticed by any writer on the subject of cataract; and I have recently seen several instances, where it had been pronounced amaurosis by many of the most experienced Oculists.*

After-Treatment.

After the operation has been performed, if pain and inflammation, with increased action of the arterial system, supervene, blood should be copiously, and if necessary, repeatedly abstracted, from the arm,

---

* Vide Case 43. and page 251.

until the pulse be considerably reduced. Should redness of the adnata, together with uneasiness and intolerance of light, still continue, leeches must be applied to the eye-lids, within the circle of the orbit, and on the side of the nose, over the part where the external nasal artery, anastomoses with the ophthalmic.

When the leeches are thus applied, there is a much larger quantity of blood abstracted, than when they are placed on the temple, or any other part equally distant from the eye; it also issues from vessels connected with those under inflammatory action, and comes so immediately from the ophthalmic artery which supplies the internal parts of the eye-ball with blood, that I have seen the most striking benefit result from the practice. The dread of increased inflammation extending from the lids to the eye-ball, has deterred many surgeons from availing themselves of the great advantage which may thus be obtained. During twelve years that I have been in the constant habit of applying leeches myself, or ordering them to be thus applied, in no one instance has it been attended with any injurious consequence. A tumefaction of the eye-lid and cheek, and an extravasation of blood in the cellular membrane, have sometimes occurred; but a lotion, composed of brandy,

vinegar, and water, has quickly removed both. Sometimes the temporal artery is of a very large size, and seems by its quick and full pulsation, to convey an unusual quantity of blood: in this case, after puncturing it immediately above the zygomatic arch, and abstracting as much blood as is necessary, I take it up with a tenaculum, and completely divide it.

I have found it much more useful to divide the trunk of the artery than either of its branches, between which there is a very free anastomosis; and I have often seen an inflammation of the eye immediately stopped, after every other means had been tried without effect, when this large channel has been cut off, even though no blood has been suffered to escape. The division of the artery produces no ill consequence, as other vessels afterwards become enlarged, and supply those parts with blood where its branches were distributed: this, however, cannot immediately take place, and during the interim the inflammation is cured. Blisters applied behind the ears, or to the nape of the neck, when there is not much inflammatory action, are generally useful. If applied to the temples during acute inflammation, they are injurious; as, from the irritation they excite, the determination of blood to the temporal arteries is aug-

mented, and the vessels of the eye become, in consequence, still more overcharged. After the pulse has been reduced by general blood-letting, the action of the heart and arteries should be kept down by the tinctura digitalis, administered in doses of ten or twelve drops every two hours, until nausea be produced: the bowels must be kept freely open. Warm and emollient applications to the eyes afford, at the first, most relief: but I always discontinue them as soon as the patient is relieved from uneasiness; and substitute in their place, refrigerents; because if they are used too long, they induce chronic inflammation in the vessels of the conjunctiva.*

No warm application is of so much use to the eye during acute inflammation, as holding it frequently, with the lids open, over the vapour of boiling water

* It has been for some time a fashion to apply hot water to the eye, in cases of chronic inflammation of the eye-ball or lids whenever the patient feels uneasiness in either. This practice cannot be too strongly reprobated; as though certainly grateful during the immediate application, still as it increases the relaxation of the conjunctiva, and the debility of its vessels, the disease is thereby augmented, and the necessity of the application rendered more frequent.

in which has been mixed a small quantity of tincture of opium. This not only relieves pain by its sedative power, when thus brought in contact with the inflamed conjunctiva, but in several instances it has actually exerted its narcotic quality, and produced sleep. I have tried the steam of water without impregnating it with opium; but although it has afforded some relief, yet it was by no means equal to that experienced when the opium was added. A cataplasm, composed of linseed powder, should be applied immediately, as warm as the patient can bear it, every time the eye has been thus steamed.

In nervous and dyspeptic patients, particular attention must be paid to the due regulation of the bowels; exercise ought also to be enjoined, which, with tonics, a generous diet, and country air, will in such cases be found much more beneficial than a rigid adherence to an antiphlogistic regimen. After the operation for solid cataract has been performed, the pupil should be kept dilated by the daily application of the extractum belladonnæ, by which the danger of its becoming contracted is in a great measure prevented.

Where the cataracts are fluid, a considerable degree of dilatation of the pupil frequently succeeds

the operation, and it sometimes continues fixed and enlarged for several weeks: in such cases, the belladonna is obviously not required. This morbid enlargement of the pupil decreases spontaneously, and the iris recovers its natural tone. It is almost superfluous to add, that the patient's eyes should, after the operation, in every instance, be defended from too much light; but the length of time necessary to continue this practice, depending on the presence of inflammation and other circumstances, must therefore be left to the judgment of the surgeon. When the operation for cataract has been performed on one eye, as long as there remains in it any degree of inflammation, the other, if not diseased, should be shaded; as, were light admitted, by the sympathy existing between both, the irritation in the eye operated on would be kept up and increased.

SECTION III.

General Observations.

In the description of the different operations for cataract, I have dwelt very particularly on the advantages derived from bringing forward into the anterior chamber, as much as possible of the lens and capsule after they have been freely divided. This practice is not to be confined to any one species of the disease, or to any age, from the infant under twelve months old, to persons who may have attained four-score years; it is equally applicable to all. In the writings of Pott, Scarpa, Hey, and others, the successful practice of placing fragments of the cataract in the anterior chamber is recorded; from an extensive experience I am very fully convinced of its superior efficacy; and still further, now, do not hesitate to bring the *whole* of the cataract forward after its nucleus has been divided, provided the anterior chamber is sufficiently large to admit of it. Any fears of injurious consequences resulting

from either practice, must proceed from a want of sufficient experience.

The long-continued inflammation produced by the mechanical friction of an undivided lens during its absorption, when placed in the anterior chamber; or even when the texture of the lens has been freely divided, if the fragments are suffered to remain behind the iris; has no doubt contributed in a great measure to excite these apprehensions. The operation I recommended is obviously different from either of these, which certainly gave some ground for such apprehensions. The former I consider as a very unfortunate circumstance, the latter I now studiously avoid. Care must, however, be taken that the needle should pass immediately through the centre of the cataract, to avoid the ill consequences of merely dividing the edges, and leaving the nucleus entire. In some instances where this has happened, I have seen the cornea become ulcerated from the long-continued pressure of the solid nucleus on its internal surface. At the time I pursued the posterior operation of Mr. Saunders, which as already stated consisted of lacerating the anterior part of the capsule, and loosening the texture of the lens, without placing any part of it in the anterior chamber, I was frequently obliged

to repeat it four or five times before I could entirely clear the pupil; on the contrary, in a large proportion of cases in young persons and adults, I now succeed at the first operation; and for the last eighteen months I have not had occasion, unless in one instance, to operate more than twice on patients of this description. I find the attendant inflammation to be much less than it was in that practice, as it is now a very rare occurrence for me to experience in children that degree, which requires general depletion; and even in adults, though the inflammation is commonly more acute, yet by attacking it early, there is no difficulty in removing it by the means recommended under the head of After-treatment. After the age of fifty, though the cataracts will often admit of being at once cut in pieces, yet this is not always practicable: as mentioned in the description of the operation for the hard cataracts of old people, it will at times be necessary to diminish its bulk, by cutting off some of its anterior part and pushing the fragments into the anterior chamber, before an attempt is made to divide the solid nucleus; its subsequent division is, however, more necessary in this, than in any other species of cataract. The

lens in old people being frequently solid and of a large size, if suffered to remain in situ even after a large portion of its anterior surface has been cut off, will generally continue for six or eight months, and sometimes for a still longer period undissolved; its absorption will also be very slow even when placed in the anterior chamber, if its nucleus be not divided. To place in a strong light the advantages of treating the solid cataract of middle-aged and old people as I have recommended, I refer my readers to an attentive perusal of a few cases where this practice has been pursued, and some others that have been treated differently.*

It will be seen by the case of Taylor, (No. 36,) aged 72, that in the left eye, in which the nucleus was divided and placed in the anterior chamber, the whole of the cataract disappeared, without any bad symptom, in less than ten weeks; while in the right eye, where the lens was placed entire in the anterior chamber, it was nearly six months in dissolving, and great part of that time the patient suffered exceedingly from pain and inflammation.

---

* Vide Cases 36——42.

Mr. V.—'s Case (37), by two operations had the greater part of the anterior portion of the cataract sliced off, and placed in the anterior chamber, where it became absorbed in as short a period as is usual: yet, nine months after the first operation, it was necessary to extract the solid nucleus, which remained undivided behind the iris. In the Case of Colonel B. (38), although the cataract denuded of its capsule had been exposed to the action of the aqueous humour nearly five months, and subsequently remained in the the anterior chamber for several weeks, yet the nucleus being undivided, it kept up a considerable degree of irritation, and in seven or eight months after the first operation required to be extracted. In Mrs. C.—'s Case (39), the cataract was of that favourable consistence which admitted of being at once very freely divided, and with so little pain that the operation was finished without her being sensible of its commencement; yet, as the fragments were not placed in the anterior chamber, they excited so much inflammation by their unequal pressure on the posterior part of the iris, that the destruction of the eye, or a closure of the pupil, was prevented only by the most active antiphlogistic plan. These unpleasant consequences are happily contrasted in the following cases—

Mrs. H. aged 40, (Case 42), in whom the cataract was of an unusually large size, and so hard that it could not be cut in pieces, but was merely divided in halves, and with the anterior part of the capsule placed in the anterior chamber, where they became absorbed in little more than five weeks. During this period it was only necessary once to apply a few leeches to the eye-lids.*—In Ann Shee, aged 64, (Case 40,) the nucleus of each cataract remained behind the iris, deprived of its capsule and anterior part for ten weeks, without apparently diminishing in size, when, being freely divided by a second operation and placed in the anterior chamber, each were in a fortnight almost completely dissolved, and the patient could then read the smallest print.—The Case of John Herbert, aged 40, (Case 42), will be found the most striking and instructive : in his left eye the cataract, which had existed for nine years,

---

* The posterior part of the capsule, which was opaque, remained in its situation undissolved ; but, a small aperture in the centre enabled the patient to read the smallest print with facility, when placed immediately opposite to the eye. The sphere of vision being, however, very limited, I have determined to perform the operation for capsular cataract. The imperfect vision resulting from a small central aperture in the capsule, was equally manifested previous to the last operation, in Case 38.

was divided into three or four parts, and the whole placed at once in the anterior chamber, where, without one unfavourable symptom in five weeks, it had entirely dissolved. In the other eye, one half of the cataract, being also placed in the anterior chamber, had disappeared in about six weeks; while the other half, which remained behind the iris, was not completely absorbed in thirteen or fourteen weeks, during the latter part of which time it kept up almost constant irritation and inflammation in the eye, requiring repeated blisters, purgatives, &c.

The above cases clearly manifest that the quick solution of the lens, when thus divided and placed in the anterior chamber, prevents any considerable and continued inflammation: the necessity of repeated operations is also prevented.

It is certain that a considerable degree of danger exists often, if the lens is suffered to remain behind the iris after it has been freely divided; and if it be not divided, whether it remains behind the iris, or in the anterior chamber, it will be indissoluble for a very considerable time, and not unfrequently require extraction. The inflammation resulting from an undivided lens when placed in the anterior chamber, seems to arise more from long-continued friction,

than from the pressure of a large lens, as is particularly shown in Case 36, where the patient's sufferings seemed much greater when the cataract in the right eye was reduced to the size of a flax-seed, than it was at first. In cases of the hardest cataract, and of the largest size, there is seldom any inflammation for the first three or four weeks after it has been placed undivided in the anterior chamber. During this period its circumference and external surface dissolve as speedily as can be wished; but, the solid nucleus alone remaining, the irritation then commences: the ill effects may, however, be avoided by the division, or entire removal of the solid central part of the lens through a puncture in the cornea. Although perfectly aware of these facts for a long time, yet, from the accident which occurred to Miss Russell, Case 21, it is only lately that I could prevail on myself in such cases to open the cornea, which I now find attended with the best consequences, and therefore strongly recommend the practice. It may be supposed by those who are unwilling to admit the full extent of the solvent power of the aqueous humour, that in Cases 37 and 38, the cataracts were of that kind which would not have become absorbed, even had the division so much insisted on been

originally made. This opinion, if entertained, is shown to be erroneous, by Case 38, where after division I intentionally left a small part of the solid nucleus in the anterior chamber, and extracted the rest, and this part speedily dissolved, without producing any ill consequence. In another of my patients the same thing has recently occurred: the centre of the cataract was of a different colour and consistency from the exterior, which was readily acted on by the aqueous humour when placed in the anterior chamber; but the centre, which I had in vain endeavoured to divide, excited considerable inflammation, by irritating the iris after the soft parts had become dissolved; I therefore extracted it through a small puncture of the cornea; in doing this, it separated into parts; one of these, about one-eighth of the whole, escaped my notice, and remained in the anterior chamber, where it however became absorbed in a month after the operation, without one unpleasant symptom.

In congenital cataracts, the success of the different operations has been peculiarly striking; as in more than seventy cases of double cataracts of various sorts, and in patients of different ages, on whom I have operated according to modes which this Work recommends, I have not experienced a single

failure; and the result has been entirely successful in all, excepting two eyes, when, by cold imprudently caught, and not from any failure in the operation, there came on subsequent inflammation, which terminated in a closure of the pupil. Relief, however, could still be administered by the operation for artificial pupil.*

If an attempt be made at once to cut into pieces

---

* One of these cases was that of a young man at Exeter, whose eye at the end of a week was entirely free from redness and inflammation, and the membranous cataract nearly gone. I then allowed him to leave his room with only a shade over the eye; when he imprudently sat for some hours in a current of air, which brought on inflammation. Having been professionally called to a distant part of the country, I did not see him till five days after this occurred; when, notwithstanding I pursued the most active measures, I could not for some weeks subdue the inflammation, during which period the pupil became closed. The other was a mendicant in Dublin, who would neither submit to the necessary after-treatment, nor remain within doors; and I saw him a short time after the operation, playing on the violin in the streets at midnight, with merely a handkerchief bound over his eyes. I was informed by a professional gentleman who has since seen and examined his eyes, that one is perfectly free from cataract, but the pupil in the other was closed.

an opaque lens, whose solidity forcibly resists the passage of the needle through it—the action of the instrument will cause a separation between the capsule and the zona ciliaris, when the cataract will be partially depressed in the vitreous humour—turn round and press with its posterior convexity against the iris, or it will pass through the pupil into the anterior chamber. All these accidents occurred in my early practice, until experience enabled me to judge, from appearances, what might be the species of cataract, and its degree of hardness. The same means made me acquainted with a further important fact, that in some species of cataract, when the density is equal, the disposition to solution is not always so. The slate-coloured congenital cataract is an example of this; for although it admits the passage of the needle through it with the greatest ease, yet it usually takes a much longer time to dissolve than any other cataract of equal or even greater solidity.* There is a considerable variation of time in the disappearance of the several species of cataract: the fluid is usually absorbed in a few days, I have often seen it become so in a few

* Vide Cases 33 and 35.

hours, and on one occasion in a very few seconds.* The membranous congenital cataracts of infants, which contain the grosser parts of the fluid lens, when placed in the anterior chamber, generally disappear in the course of a week or ten days. When the capsule is considerably thickened, as in adult congenital patients, the time required is considerably longer. The slate-coloured cataract with a transparent edge,

---

* This was in the case of a young lady nine years old, on whom I operated for fluid congenital cataracts in Edinburgh, in the presence of my friend, Mr. G. Bell, Senior Surgeon to the Edinburgh Infirmary, and of Mr. Russell, author of a New System of Surgery. Before I withdrew the needle from the right eye, the pupil was completely clear. During my attempts to detach the capsule, the milky fluid which issued from it immediately on its division, rendered the aqueous humour so turbid, as for a moment to obscure the iris. This gradually cleared; and after the operation was completed, although we all examined the eye very attentively, we could not discover the least vestige of the disease, unless a very minute portion of capsule towards the outer part of the pupil, the remainder being depressed out of the axis of vision. In the other eye the milk-like fluid disappeared as quickly; but some solid portions of lens passed into the anterior chamber, and remained some days undissolved.

is seldom removed under eight or ten weeks, unless the whole lens after division can be put into the anterior chamber at once, which in this species of the disease cannot often be accomplished. The lens, in persons in middle age, when treated as has been described, will generally dissolve in five or six weeks; but in old people, a longer time is requisite, as they frequently require a second operation.

In the posterior operation for the cure of cataract, the ciliary processes are necessarily wounded, which has been generally supposed one of the principal causes of inflammation; the opinion however is erroneous; as, after the operation for capsular cataract, I have scarcely ever witnessed subsequent inflammation.

The capsule of the vitreous humour is also wounded in the posterior operation; but the successful experience I have had in more than two hundred cases of cataract in my own practice, and the extensive field of observation I enjoyed while under Mr. Saunders's tuition, warrant me in the assertion, that this cannot be productive of any ill effect to the future vision of the patient. In the most successful operation of depression it always occurs, and also

frequently during the operation of extraction; yet even in this latter case, unless some morbid change takes place in the eye from the consequent escape of the vitreous humour, vision will not be injured. But, what places the question beyond the reach of argument, is the fact, that where the vitreous humour is partially, or even wholly disorganized, as in Cases 5 and 7, the patients have seen nearly as well as if it had been in a sound state; and in Case 35, the vision was as perfect as it ever can be after the operation for cataract.

The natural form of the pupil, and its full powers of contraction and dilatation, are very generally preserved, when the operation is performed on those species of cataract which at once admit of free division. But in the hard cataract of persons advanced in years, should a division of the nucleus by a second operation be too long delayed, as the edge of the lens becomes first dissolved, if it does not slip through the pupil into the anterior chamber, its whole surface will press on the posterior part of the iris, and produce a permanent enlargement of the pupil. This enlargement has been of great advantage by increasing the sphere of vision, in some cases, where the natural pupil has

been of a small size; and I have in no instance seen it attended with injurious consequences.

There are peculiar advantages which appear to me to belong to these operations; they are applicable to every species of the complaint, as well as to all ages, and they are capable of as great a degree of certainty as any other important operation in surgery.* It has been already shewn that there are several states of the eye, in advanced age, as well as during the earlier periods of infancy, where the operations of depression and extraction are wholly inapplicable. After depression, the lens has been known at the end of some years to return to its former situation; and during extraction, the escape of the vitreous humour has frequently produced a partial or total obliteration of the pupil; and sometimes even an entire destruction of the organ, several days after the operation was considered as successfully terminated. These are obstacles to ultimate success wholly independent of the skilful-

---

* During my residence at Exeter, I operated in my public and private practice, on forty persons in succession, of different ages, suffering under cataract, without experiencing a single failure.

ness of the operation.* The attendant danger of the absorbent practice arises from subsequent inflammation, which, however, by a careful after-treatment, will be almost in all cases under the controul of the surgeon. The power of repeating the operation without doing any mischief to the eye, is also another strong recommendation. In extraction, if the operation fail (at the first), the eye may be either totally destroyed, thereby causing great deformity; or the protrusion of the iris is sometimes so considerable as

* "Among the many causes which are apt to promote this prolapsus of the vitreous humour, may be reckoned violent terror. A peasant, from whom I had extracted the cataract, was so perfectly free from every bad symptom during the first four days after the operation, that there was but little doubt of a complete cure. A violent fire, however, unfortunately broke out in a house adjacent to the patient's, on the morning of the fifth day: the patient was much terrified and frightened by this accident, and soon after felt a most acute pain in his eye. Upon opening the eye, I discovered a prolapsus of the vitreous humour, which, if we can trust to the sensations of the patient, was not there before, and which was certainly occasioned by the fright; for he assured me that he had received no blow, nor any external injury on the eye."

Richter on the Extraction of the Cataract, page 106—7.

to keep up great pain for two or three years, as in Case 29, when there is no chance of any benefit to vision by another operation, and the patient's sufferings can then only be relieved by destroying the organ altogether. Before I changed my practice, many operations were necessary to insure perfect success, and their frequent repetition was considered as a serious objection.

The pain attending my present modes of cutting the lens in pieces with sharp instruments, is however so very trifling, that I have often performed it without the patient's being sensible that I had done so; and they almost uniformly declare, that the previous application of the belladonna is more painful than the operation itself; while from the diminished bulk and softened state of the cataract, when a second operation is judged necessary, it is always much milder, and induces less inflammation than the first; and I am so little apprehensive of any attendant danger, that I have often performed it, at the request of my patients, merely for the purpose of expediting the cure two or three weeks.

Convex glasses are necessary after the removal of cataracts. A focus of two and a half inches for near, and four inches for distant objects, is generally found to answer well; but variations in their degree

of refractive power must sometimes be made. Indeed, I have seen a few instances, as in Case 26, where the patients could see sufficiently well for all the common purposes of life, without the assistance of any kind of spectacles.

The advantages of an early operation in patients affected with congenital cataract, have already been slightly noticed. This is a subject of the highest importance; for those who have had the disease removed at an advanced age, are equally destitute of a knowledge of visual objects as the merest infant, while at the same time they are placed in circumstances far more unfavourable for its acquisition. The healthy infant examines every object with all the eagerness natural to its age; while the more aged congenital patient, from long-continued habit, has contracted a disinclination to the exercise of the eyes which he is seldom able entirely to overcome. The rolling motion of the eye depending on an involuntary action of the muscles, is therefore extremely difficult to be corrected, when the removal of the cataract has been long delayed, and it affords another obstacle to improvement in vision: this points out the necessity of an early operation. My own experience, as well as

that of Mr. Saunders, and my late colleague Mr. C. T. Johnson, sufficiently demonstrate that it may be performed as soon after birth as the defect is discovered, with the most perfect ease and safety.* Were it practicable, I would not even suffer an infant's eyes to be exposed to the light till the cataracts were removed; by which means I conceive the involuntary action of the muscles of the eyeball might be in a great measure, if not wholly prevented. Most authors who have written on the subject of congenital cataract, mention the imperfect vision of patients for a longer or shorter period after the operation, and attribute it to an original deficiency of sensibility in the retina itself. None of them, however, appear to me to attach sufficient importance to the subject, except the late Mr. Saunders; whose opinions, as expressed in a letter written a short time before his death, correspond more exactly with mine, than any others I have

---

* Mr. Saunders cured an infant of congenital cataracts, by the posterior operation, at two months old; Mr. C. T. Johnson performed the same operation with success at six; and I have been equally fortunate on a child of ten months old.

seen.* It is evident, from the powerful obstacles to the acquisition of useful vision, that unless congenital cataracts are removed during the earliest periods of infancy, the progress in the knowledge of visual objects must be afterwards very slow and tedious. This is indeed sometimes so much the case, that I have known instances, where both the patient and his friends have despaired of ultimate success, and have altogether ceased to make the necessary efforts, even after the patient had begun to see objects with tolerable distinctness. It is by no means uncommon for the friends of a congenital patient to expect, that he should obtain the power of perfect vision im-

---

* " To turn the faculty of sight to use, so as to display pre-
" cise notions of objects, demands experience, which can only
" be given by the exercise of vision with considerable attention
" for a long time. The operation has no power to confer actual
" knowledge of objects. It only prepares the eye for receiving,
" and afterwards the intellect must be employed on the objects
" so received, before any readiness can be acquired. The
" child therefore must be the object of his parents' attention,
" and be regularly and diligently exercised about large objects
" at first, and be taught to know them, then with smaller, and
" so on by degrees."

" *Vide Saunders's Posthumous Work*, p. 155—6."

mediately after the operation, and even to attribute their consequent disappointment to its imperfect execution. Parents ought therefore to be fully apprised of all these attendant circumstances of the complaint, and of the great necessity of a regular and constant attention to the future education of the patient; and they should not be discouraged because immediate success does not attend their most anxious efforts.

From an early period of my attendance at the London Eye Infirmary, my mind has been deeply impressed with the conviction, that much more than is generally supposed necessary remained to be accomplished after the removal of the disease; and every day's experience confirms me in this opinion. Since an extensive practice has opened to me a wider field for observation, I have directed a considerable portion of my attention, to the development of the various causes which retard the patient's progress in acquiring a knowledge of visual objects, as well as to the best methods of training the eyes for its attainment, and I am convinced that if proper plans, which must vary according to the capacity and disposition of different patients, were systematically pursued, not only would useful vision be

obtained by congenital patients in a much shorter period than usual, but it would fall little short of that enjoyed after the removal of the disease from persons not born blind. An intelligent person should always be appointed to superintend the management of those cured of congenital cataracts, whose sole business should be to watch and correct as much as possible those habits which impede the acquirement of vision, and to assist by every expedient which ingenuity can devise in the attainment of the desired object. To correct the rolling motion of the eyes, and to acquire the power of keeping them steady, the patient, after being fitted with spectacles, should be made to look steadfastly on one object. The muscles of the eye, and the organ itself, will soon become fatigued with this exercise; but it should be daily continued at proper intervals, by which the power of fixing the eyes at pleasure will rapidly increase. He should be made also to pick up small objects, such as grains of rice, &c.; this is also particularly useful, as it will in time enable him to judge accurately of distances, of which at first he is ignorant. Letters of a large size should be next cut out on pasteboard: as these are capable of being examined by the touch as well as sight, they will begin to

afford him a knowledge of different forms and shapes. The propensity to indolence, and want of exertion in congenital patients, even in children, is often so great, that the preceptor will have considerable difficulty in making them apply daily for as long a time as is necessary; and I have always found it regarded more as a task than a pleasure; but this must not tempt him to any relaxation in the system.

The sensibility of the retina to the impression of light increases in proportion to the degree of exercise to which the eye is subjected. It is therefore obvious that the defect in its function arises from continued inaction, and can therefore only be cured by constant application. Those who possess the blessing of sight, are in the constant and almost momentary habit of exercising the retina, while in a congenital patient all its powers are suffered to lie dormant. Even in persons not born blind, who have successfully undergone the operation for cataract, if the disease had continued for many years, the functions of the retina during this period has been much impaired, and is afterwards materially improved by exercise. If this partial want of a natural sensibility in the retina be confined to one eye, which is often the case in the slate-coloured cataracts with transparent

edges, the other eye should be covered, or the spectacle before it obscured, to prevent the passage of light, while the one affected is exercised as much as possible.

In the hope of establishing a systematic plan of educating persons who have been unfortunately affected with congenital cataracts, a young gentleman about 14 years old, on whom I successfully performed the operation, has been placed under the tuition of an able and ingenious master, who has been made acquainted with the different causes which appear to me to retard the acquirement of vision, and with the means judged necessary to be employed in his instruction. The progress this patient made while he was previously with his friends, by an attention to some of these rules, leads me very sanguinely to anticipate the greatest success from the present experiment. After his recovery from the operation he could merely distinguish colours, but was so entirely ignorant of the forms of objects that he could not perceive any difference between a square or a circle. To my great gratification, when he arrived in London nine months after the operation, he could read letters of a middle size, could help himself at table without assistance, walk alone in the streets,

&c. ; and I have great reason to hope that at some future period I shall be able to lay before the public the favourable result of my efforts, assisted by those of the intelligent master on this interesting subject.— On the contrary, I have frequently seen instances where the operation has been attended with equal success, yet, owing to a want of proper attention afterwards, the patient has derived little or no benefit from it. A young lady upwards of twenty years of age, one of the first persons I operated on at Exeter, to whom I was enabled myself to pay at first a good deal of attention, a month after she was cured, could distinguish the minute-marks on a watch-dial, and see a hair when plucked from her head ; but so great was her indolence, that it was only by constant watching, she could be urged to any kind of application ; and I have learnt that since her return home she has entirely given up every exertion for the improvement of her sight, and now remains nearly as helpless as ever.—The little attention which appears hitherto to have been paid to a subsequent education, in the constant exercise of the improving powers of vision, and the wish of impressing its importance still more strongly on the minds of those

who are not sufficiently aware of the prevalence of the retarding causes, have induced me so considerably to extend these observations; and I feel a strong hope that, by the hints which they contain, they will materially assist the efforts of many anxious parents, in the future education of such of their children as have undergone the operation for congenital cataract.

Before I dismiss a subject with which the name of Mr. Saunders must ever be associated, I trust I shall be excused for introducing a public acknowledgment of the obligations I owe to my deceased friend and preceptor. To his disinterested liberality I am indebted for that general knowledge of diseases of the eye, which has led to the practice of the different operations recommended in this work. Besides the feelings of gratitude by which I am actuated, I have the additional motive of thus vindicating his character from the charges of secresy resulting from a want of liberality, which since his death have been brought against him; his conduct to me being in itself a refutation of these charges. He not only allowed me gratuitously to witness, and assist in, all his operations, as well private as

public, for nearly a year and a half that I remained under his tuition, but he afterwards assisted me by every means in his power in the establishment of the West-of-England Infirmary for curing diseases of the Eye, and sanctioned the infant institution, by allowing his name to be placed in the list of its medical officers. With a view of still further promoting my professional advancement, he in the most friendly manner publicly announced in his Official Letter to the Governors of the London Eye Infirmary, the instructions he had given me, and the extensive field of improvement which had been opened to me by witnessing his practice, as will be seen by the following extract, taken from his letter in the 4th Annual Report of that Institution:

"This process for curing the cataract in children, " together with other observations relative to the eye, " which I am about to publish as soon as the neces- " sary arrangements can be made, has already been " freely communicated to an individual, and the ample " scene of experience which this Infirmary affords, " opened to his view from a disinterested wish to " promote his professional object. Mr. Adams has " since settled in Exeter, and there established a " charity on the model of this institution. This

" event I could not refrain from noticing, because it " must excite in your minds, and the minds of the " Governors, the grateful reflexion that your bene- " volence has given life and activity to an institution " which has benefited society not only in its own " operation, but by giving direct origin to an esta- " blishment producing its contingent of good in " another part of the kingdom. That which was " so liberally given in the spirit of private friend- " ship, has been so long withheld from the public " in the hope of making it more worthy of ac- " ceptance, and not through a mercenary motive, " as some have malignantly observed, or an incli- " nation to boast the possession of a secret."

I had no claims on his generosity or friendship; our intimacy originated from having both served our apprenticeship to the same general practitioner, and in my having assisted in preparing his subjects for anatomical demonstration, during one of the years I attended the different classes at the united Hospitals of Guy's and St. Thomas's. The unreserved intercourse which subsisted between us for the period I enjoyed the peculiar advantage of being his pupil, and sole assistant at the London In-

firmary for curing diseases of the Eye,* and the friendly correspondence we continued till within a fortnight of his death, enable me positively to assert, that his withholding from the public the long-promised communication of his operations for cataract and other diseases of the eye, proceeded neither from a want of candour nor any selfish motive of secresy. He announced his intention of publishing on these subjects, some time previous to my quitting the Infirmary; but he was prevented by various causes from fulfilling his intentions, and chiefly by the frequent attacks of the painful disease under which he so long suffered: this disease, to which he feelingly alluded in some of the last letters I received from him, at length deprived me of one of my best and most highly valued friends—the blind and diseased poor, of a zealous and humane benefactor—and the

---

* Soon after I left London, two gentlemen were permitted by Mr. Saunders to attend the practice of the Infirmary for three months each, on condition (as I was informed by one of them, who came to Dublin from a distant part of Ireland, to see me operate,) that they were not to witness Mr. S.'s operations for cataract.

profession of a man eminently distinguished for his anatomical and pathological knowledge,—by which he was enabled to investigate and successfully to treat many diseases of the eye, which, before his time, were either wholly unknown or but very imperfectly understood.

CASE XIX.

The beginning of September 1810, four daughters of a widow lady from Glasgow, of the name of Russell, came to me at Exeter; all of them were born blind of cataracts. On the three eldest, operations had been unsuccessfully performed by an eminent oculist in London, who declined making any attempt on the youngest, Miss Grace Russell, aged seven years. September 15, I operated on both her eyes. In the right there was an opaque and thickened capsule, containing a small portion of lens. In the left, the cataract was in a fluid state, and the capsule opaque. I cut in pieces the cataract in the right eye, and projected the greater part of it into the anterior chamber. The needle was as freely passed through both portions of the capsule of the fluid lens in the left eye. The escape and consequent admixture of the milky fluid rendered the aqueous humour completely turbid, and it did not again become clear in less than three days. A slight inflammation succeeded the operation in this eye. In the evening six ounces of blood were taken from the arm, and next morning four leeches applied

to the eye-lids, which, with emollient applications and aperient medicines, removed all inflammatory symptoms in four days. The pupil remained enlarged and fixed, as I have often observed after the operation for fluid cataract. In the right eye there was not the least inflammation; the sixth day the whole of the cataract had become absorbed, and the pupil was of its natural appearance. October 10, little change having taken place in the capsule of the left eye, I repeated the operation, detached the capsule from the ciliary processes, and afterwards depressed the whole of it below the edge of the pupil, excepting a very small portion towards the outer margin of the iris. This portion, however, shrunk up, and could not be discerned, when the pupil had regained its proper size: this was in four or five weeks, at which period it also possessed its natural sensibility to light, and was perfectly circular. The vinum opii had been applied thrice a day, which seemed to assist in restoring the natural functions of the pupil. The rolling motion in this patient's eyes was so great previous to the operation, that she had not the power of fixing them for a single instant; she also had a considerable degree of strabismus in one eye, as frequently occurs in persons who labour under

congenital cataract. After the operation it was also extremely difficult to prevail on her to keep her attention fixed on any one object: yet, notwithstanding these obstacles to the acquisition of vision, she had learned the alphabet in large-sized characters at the end of a month after she had been allowed to use her eyes; and when I saw her in Glasgow, November 1811, on my return from Ireland, I found her eyes much more steady, and her sight considerably improved, though probably not in so great a degree, as had the eyes been more constantly exercised.

CASE XX.

Miss Catherine Russell, ætat. 13, had capsular cataracts in both eyes when she was brought to me, the fluid lens having been previously removed by an operation with the needle. The pupil of the right eye was fixed and much dilated; that of the left was of the natural size, and indicated considerable sensibility to light. She could discern light, and

colours with both, and her eyes were not so unsteady as her sister's. All these circumstances led me to hope a favourable result from the operation. The beginning of October, I operated on the left eye, and perfectly cleared the pupil by detaching the capsule, which was very much thickened, in part from the ciliary processes, and afterwards depressing it.—November 6th, the operation was performed on the right eye, in which I was enabled to break in pieces the capsule; some of these pieces I pushed below the axis of vision. There was no subsequent inflammation in either eye, and the pupils in both were as entirely cleared from the disease as could be wished; yet very little improvement in vision succeeded, although the case had promised so favourably.

CASE XXI.

Miss Russell, nineteen years old, had also capsular cataracts, resulting from an operation in each eye with the needle, by which the fluid contents had been previously removed. In the right eye I found the capsule of the lens opaque, and much thickened; the pupil was dilated, and the collapsed membrane firmly adherent to the posterior surface of the iris through its whole extent: with this eye she could perceive light, colours, and the motion of objects. In the left eye, although there was a clear aperture in the centre of the capsule, yet as the strongest light made no impression on the retina, I did not attempt any operation on it.

October 9th 1810, I operated on the right eye. I experienced great difficulty in separating the capsule from the posterior surface of the iris, which, however, by gentle and repeated efforts, I at length accomplished, with the exception of a very small portion at the upper part. This slight adhesion prevented me from entirely lodging the opaque membrane in the anterior chamber, which it was

my intention to have done, not being then so fully aware as I am at present, of the insolubility of the capsule when undivided. The iris having been much irritated during the disengagement of the capsule, some pain and redness ensued, which were removed by once bleeding in the arm, aperient medicines, emollient applications, &c. At the end of a fortnight, as the capsule appeared to have partly receded through the pupil, I resolved to extract it through a puncture in the cornea; an operation I had performed a few weeks before with great success.* The beginning of November, assisted by Mr. J. White of Exeter, after having fixed the eye by introducing Pellier's speculum under the lid, I made a small opening with a cataract knife in the outer side of the cornea, about a line anterior to the sclerotic coat. No sooner, however, had I withdrawn the knife, than by the involuntary action of the muscles of the eye-lids, the speculum was pressed so forcibly against the eye-ball that a considerable protrusion of the iris immediately followed. I instantly removed the speculum, fearing the pupil

* See Case 35.

might become entirely obliterated, as this young lady had not the smallest control over any of the muscles connected with the eye. I next attempted to extract the capsule; but the motion of the eye was so incessant, that it rendered repeated efforts unavailing, and I waited in vain for more than an hour in the hope that I should be able to accomplish this, or to return the protruded portion of the iris through the puncture. Disappointed in both objects, I resolved, if possible, to remove the protrusion, with a pair of curved-pointed scissars. I partly succeeded after repeated trials; but the eye rolled so much as to prevent me from removing it entirely. No inflammation succeeded. In ten days a weak solution of argentum nitratum was dropped into the eye twice a day; and the remaining portion of the prolapsed iris gradually decreased, until it wholly disappeared. Having left Exeter early in December, I did not again see Miss Russell until March 1811. The pupil was then transversely oblong, and extended from its natural situation to the cicatrix in the cornea; the capsule was somewhat wasted, but still occupied a large part of the pupil. On my return from Dublin, November 1811, Miss Russell followed me from Glasgow to Edinburgh, where, assisted by my friend

Mr. G. Bell, I depressed the remaining portion of capsule below the axis of vision, and left the pupil quite clear. A morbid sensibility to light remained for a few days; but it subsided by the application of a refrigerent lotion. Mr. Bell has since informed me, that she returned home in a fortnight, from the time of her arrival in Edinburgh; her vision was then much improved, and she was able to distinguish large letters with tolerable correctness.*

* The other sister had entirely lost one eye in an unsuccessful operation of couching by a surgeon of Glasgow. The cataract in the other eye had been extracted in London; but a considerable protrusion of the iris ensued, and the pupil was much lessened in size: when I saw her, it was still sufficiently large to admit the passage of light; yet as she was unable to discern objects, I did not judge it expedient to perform any operation. There was a fifth daughter in this family also born with cataracts, who died while an infant.

CASE XXII.

Master P. only son of Captain P. of Calloden in Ireland, and two of his younger sisters, were born with cataracts; the disease was first observed in the boy, a month after his birth. When seven years old, his father brought him to London, with the intention of having an operation performed, and with this view consulted the most eminent oculists in the metropolis. The opinions given, however, were, that no operation could be undertaken with any prospect of success till he should be of an age to understand the necessity of keeping his eyes steady. With these opinions Captain P. was satisfied, and returned home. In the early part of 1811, he wrote to me requesting that I would come to Ireland, to operate on his three blind children, if I thought his two youngest daughters were old enough to undergo the necessary operation. From my experience of its success in children of the tenderest ages, I entertained no doubt of a favourable result, and therefore acquiesced in his proposal. On my arrival in Dublin, in May 1811, I found Master P. and his youngest sister laboured under fluid cataracts

with opaque capsules. Those of the elder sister were slate-coloured with transparent edges; I operated on all three, June 1st 1811, in the presence of J. Wild, Esq. the intelligent author of Travels in America, &c. An hour after the application of the belladonna, I made a transverse division of the capsule in the manner described, page 138, and afterwards cut it in pieces close to the edge of the pupil. During the latter part of the operation I was unable to see the point of the instrument, from the fluid cataract having rendered the aqueous humour turbid. Some pain and redness in the eyes succeeded, which were in a few days removed by general and topical blood-letting, aperients, &c. In less than a week the absorption of the milky fluid was completed, when the pupil of the right eye was perfectly clear and circular, and but a very small portion of capsule was visible in the left. Both pupils remained for some time fixed and considerably dilated, but they again recovered their natural size and functions. This is the young gentleman who, as already mentioned, has been placed in London under the tuition of an able master, Mr. Robinson of Lincoln's-Inn Fields.

CASE XXIII.

Miss M. P. aged thirteen, was observed, when an infant, to labour under an imperfection of sight; but it was not until she attained her fifth year that her family suspected any positive disease to exist in her eyes; and they were not even then certain she had cataracts, as the pupils appeared very unlike those of her brother and youngest sister, and her vision was so much better than theirs. On examining her eyes I discovered she had slate-coloured cataracts with transparent edges; through these the rays of light passed sufficiently to enable her to read small print in a moderate light. I operated on this young lady with the two-edged needle, and, according to my usual plan, cut the cataract into small pieces, and placed as many of these as I could in the anterior chamber. During the first fortnight no unfavourable symptom occurred; but at the expiration of that period, without any assignable cause, acute inflammation came on, accompanied with pain and intolerance of light. Notwithstanding a strict adherence to a cooling and antiphlogistic plan, this continued for some weeks, when I changed the

mode of treatment and recommended the employment of cinchona thrice a day, with a generous diet, sea air, and sea bathing. This alteration of practice produced an almost immediate amendment, which continued to increase until the inflammation wholly subsided, when I found the pupil of the left eye entirely free from cataract, and the other nearly so. In ten weeks she was able to distinguish the most minute objects, by candle-light, which before the operation she was totally unable to do. The pupil of the right eye was perfectly circular, that of the left a little oblong; her vision is now as good as it ever can be after the removal of the crystalline humour, and is in no respect inferior to that which results from the operation on persons whose cataracts were not of the congenital kind.

CASE XXIV.

Miss Francis Elizabeth P.—, seven years old, laboured under fluid congenital cataracts with opaque capsules; she underwent the operation on the same day as her brother and sister. With one

stroke of the needle I made a large aperture through both the anterior and posterior portions of the capsules; their fluid contents consequently became extravasated, and mixed with the aqueous humour. In a week it was absorbed, and no vestige of the disease remained, excepting a very minute portion of the opaque capsule around the margin of each pupil; a slight inflammation ensued, which was removed by the application of a few leeches, aperients, and emollient applications. For several weeks the pupils remained dilated and immovable. Although the aperture in each capsule was of a large size, yet as I was desirous of detaching as much of them as possible from the ciliary processes, I prevailed upon the parents of this young lady to allow me to repeat the operation, which I did the beginning of August; when I happily succeeded in removing the remainder of the opaque capsules. There was no consequent inflammation; and in September, when the patient left Dublin, she had learnt the alphabet, and, by a degree of assiduity unusual in children of her age, was enabled to direct her eyes with much more precision than her brother. It is somewhat remarkable, that after her eyes had recovered from the effects of the operation, she pointed out objects more

accurately than he could, although previously his perception of light and colours had been much more distinct than hers.

CASE XXV.

Francis Saxy, of Beer-regis, Dorset, aged 18, applied to me at Exeter, in the summer of 1810. His mother stated, that he was born with cataracts, that she had taken him to London, six years before, when an operation had been unsuccessfully performed on his left eye, by an eminent oculist, who had refused to make any farther attempt on it, or to do any thing to the other. On examination, I found the capsule in the left eye opaque, much thickened, and destitute of the lens. In this eye, the vision was confined to a mere perception of light and colours; but with the other, in which a small part of the lens remained within the capsule, he could see to walk without assistance. The 21st of June 1810, I detached in the usual manner the thickened capsule in the left eye, and depressed it below the axis of vision without difficulty; but in the right, some time

and much trouble were required, in order to divide the thickened capsule sufficiently to allow the escape of the pieces of cataract: these as well as the opaque capsule I at length succeeded in placing in the anterior chamber. Much pain had been occasioned by the difficulty attending the separation of the capsule, and in the afternoon considerable inflammation came on. Venæsection was performed, but no blood was lost, as the patient fainted during the operation. Six leeches were therefore applied, which abstracted a considerable quantity of blood, and relieved him from all pain; but the redness of the eye and intolerance of light continuing, the third day I ordered four more leeches, and a blister to the temple. By these means, together with the use of aperients and emollient applications, every dangerous symptom disappeared in four or five days. A week after the operation, all bandages were left off, the pupil was perfectly clear, and he could see distinctly. The pieces of cataract were also absorbed; but scarcely any change had taken place in the capsule. In little more than three weeks after the operation, by the application of the vinum opii three times a day, and the occasional employment of a collyrium composed of the sulphate of zinc, all weakness and irritation having

been completely subdued, I allowed him to return home. Previous to his departure from Exeter the capsule in the right eye had considerably contracted, and left four-fifths of the upper part of the pupil clear; which enabled him to distinguish, and point out with a probe, the smallest letters. Eighteen months after these operations I learnt that the capsule had not entirely disappeared, but was so much diminished in size that it no longer obscured any part of the pupil.

CASE XXVI.

William Saxy, twenty years old, brother to the former patient, had also congenital cataracts, which I found to consist of opaque and thickened capsules containing some portions of lens. With the right eye he could merely discern light and colours. With the left, he distinguished large letters if held within two inches of the eye, and with his face being turned from the light; but the sphere of vision was so limited, that he could take in but three or four at a time, and even that power was wholly lost when the eye was exposed to a strong light.

The oculist, when he operated on his brother in London, informed this young man that it would be hazarding the little vision he enjoyed, were he to attempt to perform any operation, and advised him to remain contented. I operated on both eyes the 21st of June 1810. After cutting in pieces the capsule and unabsorbed lens in the left eye with the two-edged needle, I pushed as many of the fragments as possible into the anterior chamber. In the right eye, the capsule from its greater toughnesss could not be so easily separated. However, I succeeded at length in accomplishing this, and placing the whole of the nucleus in the anterior chamber; but the capsule still occupied the greater part of the pupil. Being attacked immediately on his return to his lodging with pain and increased heat in this eye, he was bled, but fainted after losing about six ounces. The pain and heat however abated, and he passed a comfortable night. The symptoms of inflammation having increased, the next day I ordered six leeches, and emollient applications to the eye, besides a blister to the temple. Aperient medicines were also administered almost daily. By these means and the occasional application of leeches, every symptom

of inflammation was overcome in the course of three weeks.

In the left eye no inflammation followed the operation; and so rapid was the solution of the cataract, that in a month it was entirely absorbed, leaving the pupil perfectly circular and sensible to light. The fragments of cataract which had fallen into the anterior chamber of the right eye were now also absorbed; but the capsule seemed undiminished, and still occupied the whole extent of the pupil.

August 10th, I repeated the operation, and found the capsule very firmly adherent to the iris; this appeared occasioned by coagulable lymph, effused during the inflammation, which rendered it very difficult to detach. Having effected the separation, I placed a part below the pupil, and the remainder on one side, behind the iris. No inflammation of any consequence ensued. For a few days the eye could not bear the light, and the cornea was rather dull; but by the employment of the vinum opii, and a zinc lotion, for a fortnight, this eye became as free from inflammation as the other. The pupil is perfectly circular except at one point,

and he can see equally well with both eyes to read the smallest print without the assistance of spectacles, and in no respect is their vision different. His cure was completed in nine weeks, and he has since lived with me in the station of a footman. At first he was an imperfect judge of distances, but in this respect he has become much improved, though he still finds some difficulty in snuffing a candle, or pouring liquids into a small glass.

CASE XXVII.

Mr. Purkis, aged 30, organist of St. Clement's, Strand, became my patient in the spring of 1810. He laboured under congenital cataracts consisting of opaque capsules inordinately thickened, which contained some portions of unabsorbed lens, and was of that species termed *Elastic cataract.* Both pupils were very sensible to light, and he could discern brilliant colours. He informed me, that when a lad, his eyes had been examined by Baron De

Wenzel, who not only declined operating on him at that time, but strongly dissuaded his father from permitting any operation to be performed at any future period. Several eminent oculists, to whom at different periods he subsequently applied, concurred in the opinions given by the Baron. The rolling motion in Mr. Purkis's eyes existed in a much greater degree than in any patient I had ever seen, which rendered him unable for a considerable time after the removal of the cataracts to keep his eyes steadily fixed on any particular object. The beginning of June 1810, I operated on the right eye, at his father's house in Chancery-lane, in the presence of Mr. Ware and several other professional gentlemen, at which period I had not discontinued the use of the one-edged needle, and therefore used it on this occasion. I found the capsule infinitely harder and more dense than any I had ever met with, requiring the instrument to be kept several minutes in the eye, before I could make an aperture sufficiently large to admit the escape of the fragments of the nucleus. This I at length accomplished, and placed the whole of them in the anterior chamber. During my attempts to divide the capsule,

if I made a considerable pressure with the needle downwards, the opaque body would entirely disappear below the pupil; but no sooner was the pressure withdrawn, than it instantly resumed its place, as if touched by a spring. Some inflammation ensued in the afternoon, which was entirely removed by twice bleeding in the arm. As I was obliged to leave London three days after the operation, I did not see Mr. P. till the September following, when he came to me at Exeter, for the purpose of undergoing an operation in the left eye. The upper part of the pupil of the right eye was by this time perfectly clear, and the portions of cataract which had been placed in the anterior chamber were entirely gone, but the condensed capsule still remained, and occupied the lower part of the pupil.

A few days after his arrival, I operated on both eyes. I placed the whole of the remaining capsule of the right eye, in the anterior chamber, which left the pupil clear. In dividing the thickened capsule in the left eye, I experienced much less difficulty than in the first operation on the other, as I now used my two-edged needle; and I afterwards placed the pieces of cataract contained in the capsule in the anterior

chamber. There was no subsequent inflammation in either eye, and on the fifth day the redness had entirely disappeared, unless where the instrument entered; but I had the mortification to find the capsule in the right eye had resumed its former station behind the iris, and floated in the vitreous humour immediately posterior to the pupil. In less than a month all the fragments of the lens which were placed in the anterior chamber of the left eye, having been absorbed, I repeated the operation, and separated the capsule into several portions; some of these I carried forward through the pupil, and the rest I pushed below its edge. I also a second time placed the undivided capsule of the right eye in the anterior chamber; but the next morning it had returned through the pupil, and become spontaneously so much sunk in the vitreous humour, that only a very small part of it was discernible. I suffered it to remain, as, from the incessant and rapid motion of the eye, it would have been impossible to extract it without the assistance of a speculum, which it would have been dangerous to use. No inflammation succeeded in either eye: five days after the operation he was sufficiently well to perform on several instruments at a public concert made for

him at Exeter, and in as many more he returned to London.*

CASE XXVIII.

In the spring of 1811, I operated in London on a young lady about nine years old, affected with capsular cataracts. The cataracts were originally fluid; but having been twice operated on previous to my seeing her, nothing remained but the capsules, which were very opaque and much thickened. An aperture the size of a large pin's head had been made in each capsule a little on one side of the central points; but as the pupils were

---

* The professional avocations of this patient and the rolling motion of his eyes, have hitherto prevented him from reaping all the benefit to be derived from the operation. The rolling of the eyes, however, is very much corrected, and he has acquired the power of fixing them at pleasure. He has learnt to read musical characters, to tell the hour with the greatest accuracy on a watch-dial, or by a church clock at a considerable distance, and his power of vision continues to improve. Since his return from Exeter, he walks without a guide by day and night, which he never ventured to do before the operation, and has now entirely laid aside the use of spectacles, except to view minute objects.

unusually large, scarcely a fourth part of them were cleared. In the presence of Mr. Ring, surgeon, of South Molton-Street, with my curved-pointed needle, I separated the capsule of the left eye from its ciliary connexion, except towards the outer angle of the eye, by carrying the instrument in the arc of a circle from the internal to the external canthus, and placed it out of sight when the pupil was under the influence of the belladonna. In the right eye I left the connexion with the ciliary zone in the lower part, and completely detached the rest of the capsule, which I pushed below the axis of the pupil. It however partly rose again; but having frequently seen the diminutive size to which the opaque capsule contracts, after being so much detached from the ciliary processes, I did not attempt to cut it in pieces for the purpose of placing it in the anterior chamber. The third morning after the operation the pupil of the left eye had recovered its natural size; it was clear, circular, and sensible to light, and not the smallest part of the capsule was visible. In the right eye, the capsule had already begun to contract; and as I was obliged to leave London, I left the young lady in the charge of my nephew Mr. Hockin; who has since informed me, that in less than a month the

capsule had, as I expected, shrunk into a very small compass, and was situated so much below the lower margin of the pupil, as to be visible only when the pupil was in a state of dilatation. I have not seen this young lady since my return to London, but am informed both pupils are now equally clear; from which I infer, that the capsule in the left eye is either entirely absorbed, or so much contracted as not to be discernible.

CASE XXIX.

Early in December 1811, I was consulted by Mr. Benton of Islington, aged eighty, who in the year 1807 had undergone the operation of extraction for cataract, in both eyes. In the left eye the operation totally failed, almost the whole of the iris having protruded through the section of the cornea, and formed a tumour of a conical shape, which extended considerably beyond the edges of the lids, and prevented their becoming at any time closed. He suffered very acute pain in this eye for several months after the operation, and for three years it proved a continual source of irritation and uneasiness, which had not entirely ceased when he first consulted me. In the right eye there appeared to have been an escape of the vitreous humour, which had dragged a large portion of the iris through the section of the cornea; the lower part of which was rendered opaque, by the inflammation that succeeded the operation. About two-thirds of the upper part of the pupil still remained, but the rays of light were prevented from passing through it, by the capsule, which had become opaque, and firmly adherent to

the posterior part of the iris, thereby preventing the contraction and dilatation of the pupil. For the first twelve months after the removal of the cataract, he had been able, though with considerable difficulty, to read common-sized print; but from that period his vision gradually decreased until he applied to me, when he could scarcely see to avoid the furniture of his room.

December 18th 1811, I operated on the right eye in presence of Mr. Hole, of Highbury-Terrace, Islington, the family surgeon. The capsule was extremely tough, and so firmly attached to the posterior part of the iris, and to the cicatrix of the cornea, that it was with difficulty I could separate them. Having however accomplished this, and freely lacerated the capsule, I left the whole of the remaining pupil perfectly clear. The next morning he complained of a slight pain in the eye, and his pulse was somewhat accelerated. Some blood was abstracted from the arm, which immediately stopped all increased action; and no other unfavourable symptom occurred during his convalescence. On the fifth day from the operation the bandages were removed, and a shade substituted in their stead; and on the tenth he read small print in my presence, assisted by

cataract spectacles. He was not confined to his bed during any part of the treatment; his vision improved progressively; and on the first of January 1812, he assured me that he saw as well as any man, whose eyes had never even suffered from disease, could at his age hope or expect. Topical applications were employed both before and after the operation, to remove the chronic inflammation in the right eye, and the morbid sensibility which still remained in the left, caused by the former unsuccessful operations of extraction; these applications considerably relieved him from the painful sensations with which he had been before so constantly harassed.

CASE XXX.

George Broad, from the parish of St. Guinans, Cornwall, applied to me the middle of June 1810, on account of blindness in both eyes, resulting, as he informed me, from unsuccessful operations of depression for cataracts several months before. Both pupils were contracted to the size of a pin's

head, and these small apertures were rendered impervious to the rays of light, by the capsules having become opaque and firmly adherent through their whole extent to the posterior part of the iris, in consequence of violent inflammation which had succeeded the operations. Before they were performed, he had seen sufficiently well to pursue his usual employments as a labourer, but when I saw him he could only distinguish light from darkness. I operated on both eyes in the manner already described with the curved needle. On separating the adherent capsules from the iris, and pushing them below the axis of vision, the pupils instantly became enlarged, clear and circular, possessing their full and free powers of expansion and contraction. No appearance of inflammation followed, and he was sent home a fortnight after I operated on him, with as good sight as patients ever enjoy after the removal of the crystalline lens.

CASE XXXI.

Master R. son of — R—, Esq. Ardee-House, Ireland, became my patient at Bath, May 1810. He had lost one eye during childhood from small-pox, and when he consulted me had cataract in the other, occasioned by a blow received from the bough of a tree about six months before. He could distinguish large objects; but the pupil was much contracted from adhesions of the capsule and iris, and had in a considerable degree lost the power of dilatation. As this young gentleman's vision, though very imperfect, was still useful, his father proposed, before I performed an operation, that Mr. Ware should be consulted, to ascertain his opinion whether under all the difficulties of the case it would be advisable to attempt any. Mr. Ware with great candour acknowledged it was a case in which extraction was wholly inapplicable, and recommended the operation I had previously proposed.

May 1810, I accordingly separated the opaque capsule from the iris, the lens being nearly wasted; but the patient becoming restless, I did not succeed in placing it in the anterior chamber. No inflam-

mation ensued. About a month afterwards I repeated the operation, when I carried the whole of the undivided opaque body forward through the pupil; finding it so tough and hard that it was not possible to cut it in pieces. As no appearance of inflammation followed, I allowed the patient to quit Bath, and assured him that in time the capsule, with its contents, would dissolve and be absorbed. Twelve months afterwards, when in Dublin, I again saw my young friend, and was much surprised to perceive, that though the small remaining part of the cataract was entirely dissolved, yet a large portion of capsule still remained immediately before the pupil, adherent to the internal surface of the cornea, which prevented it from sinking below the axis of vision. My proposal of detaching the capsule from this adhesion being assented to, I introduced the two-edged needle through the cornea anterior to the iris, and with some difficulty accomplished my object, when the capsule instantly sunk to the bottom of the eye, and left the pupil entirely clear except at its upper margin, where there remained a very small portion of capsule, (which had never been separated from the iris), and which was not larger than the head of the smallest sized pin. A slight degree of redness in

the eye succeeded, but was speedily removed by the application of leeches, and a cold wash constantly kept to the eye-lids. The portion of capsule which had been detached by the last operation floated in the anterior chamber as the position of the head varied. When the patient bent his head forward, it rose up before the pupil, and consequently for the time obscured his vision, but on resuming an erect posture he could see distinctly the minutest objects, when assisted by a proper glass. I had it in contemplation to extract it through a small puncture of the cornea, but as this could not be done without making use of the speculum, I gave up the idea, hoping, from the diminution in size it had already undergone, that it would soon entirely disappear. Having however heard, since I left Ireland, that it had excited some inflammation by mechanically irritating the iris, I wrote to the young gentleman's mother, to ascertain its present state, who informed me, there certainly had been some inflammation since I saw him, but it had now entirely subsided; that the capsule was much reduced in size, and her son was prosecuting his studies with great industry and success.

CASE XXXII.

Robert H. Esq. 16, Great Cumberland-Street, Portman-Square, aged 26, had a solid light-coloured cataract in his left eye, which had been observed more than fifteen years before. In the right eye the capsule was partially opaque throughout its anterior surface, but he could read pretty distinctly by the assistance of a deep convex glass, when the pupil was not much contracted by a strong light. At an early age he was taken to an oculist of eminence, who declined operating on his right eye altogether, but agreed to extract the cataract in the left if the friends of the patient wished him to do so, though he would not recommend the operation. The young gentleman was therefore suffered to remain in the state I have described until April 1811, when being in London I operated on his left eye in the presence of that respectable surgeon Mr. Adair Hawkins, of Great Marlborough-Street, and some other professional gentlemen. I used my two-edged needle in the usual manner, cut every part of the opaque lens and its capsule into pieces, and placed most of them in the anterior chamber, which was nearly filled with

the fragments. About a sixth of the upper part of the pupil was cleared, and he read in five days with this eye, assisted by a proper glass. No inflammation ensuing, I allowed him to come into the drawing-room a week after the operation. Having left London soon after, I know not how long it was before the cataract completely disappeared, as his friends did not accurately mark the period; but on my return from Ireland in November following, no vestige of the disease remained; the pupil was perfectly circular, and possessed its natural functions. Early in December, the operation was performed in the right eye, in the presence of Doctor Ross of Edinburgh. The opacity, as I expected, was confined to the capsule, the lens being firm, and perfectly transparent. After dividing both the capsule and lens in halves, I cut them into several pieces; all these I lodged in the anterior chamber. No inflammation or pain in the eye ensued; but in the evening the family surgeon, to whom I had given a discretionary power respecting bleeding, finding the pulse somewhat accelerated, very judiciously took off six ounces of blood, which reduced them to the natural standard. At the end of a fortnight a small carbuncle formed on his cheek, and excited con-

siderable inflammation in the surrounding integuments, which was communicated to the eye-ball itself. This however ceased, as soon as the carbuncle was cured. Five weeks after the operation, the lens had wholly dissolved, and in a moderate light the pupil was completely transparent; but when much dilated, some of the circumference of the capsule was still visible in its upper and lower part, which has since disappeared. The pupil in this eye in every respect looks as well as the other, and his vision in both is as good as it ever can be after the removal of cataracts.

CASE XXXIII.

Mr. John Scoles, aged eighteen, 210, High Holborn, at seven years of age was sent to school; where being found incapable of seeing distinctly, he was taken to an eminent oculist, who thought his imperfect vision arose from near sight, and advised country air and tonic medicines; although his health improved under this regimen, his sight was not benefited. When thirteen years old, he was

taken to another oculist, who immediately pronounced the case to be cataract, and the operation of extraction on the left eye was shortly afterwards performed. The cataract was extracted; but an almost entire closure of the pupil ensued, for which he underwent three unsuccessful operations. In April 1811, I was consulted, and found in the right eye a slate-coloured cataract with a transparent edge. With this eye he could explore his way when the light was not vivid. The pupil of the left eye was obliterated, unless just at its upper margin; behind this small aperture there was an opaque capsule, which prevented any other perception than that of light and colours.

April 7th 1811, I performed the operation for cataract on the right eye, and cut the capsule and cataract in pieces very freely, placing as much of the latter as I could into the anterior chamber. A slight inflammation succeeded, which was removed by once bleeding in the arm, emollient applications, &c. By applying the extract of belladonna in its concentrated state to this eye rather too soon, some redness was re-induced, but it disappeared by the use of cold applications. I left London in a

fortnight after the operation, and did not again see my patient till my return in December, when both lens and capsule were entirely removed, and the pupil was perfectly clear, circular, and sensible to light. His friends informed me, the parts of the cataract that had been brought forward, disappeared in five or six weeks after the operation; but the remainder, which was left behind the iris, was not entirely absorbed under five months. He had learnt to read print of a small size a month after he was fitted with spectacles, and is now capable of seeing both near and distant objects with precision. Encouraged by the benefit received in this eye, the young man's father requested I would operate for artificial pupil in the other. This I attempted, the end of December 1811; but, the vitreous humour being entirely disorganized, I was prevented from making the division in the iris as large as I wished; so much of that humour escaped by the side of the instrument, as to render the coats of the eye quite flaccid, and the small aperture I did make became closed. From the repeated operations performed in this eye previous to my seeing it, the organ was in so irritable a state that it did not perfectly recover its tone for

some months, although no inflammation of any consequence succeeded. The patient and his friends are now so well satisfied with the vision he enjoys, that they do not wish for any farther operation.

CASE XXXIV.

John Croker, of St. Stephen's, near Saltash, aged 40, by trade a carpenter, was recommended as an in-patient of the Exeter Eye-Infirmary, by the Rev. Mr. Buller of Saltash, for the purpose of undergoing the operation for solid cataract in both eyes, which was performed the day after his admission. I used the double-edged needle, and divided the cataract in the right eye in halves. The lower half I placed in the anterior chamber without any farther division, and allowed the other to remain suspended in its natural situation. In the left eye having introduced the needle too close to the iris, I withdrew it without making any attempt to divide the cataract. In the afternoon pain and redness supervened, w h a

watering in the right eye, for which I abstracted twenty ounces of blood from the arm, and applied a blister to the nape of the neck. These means, with warm applications, effectually removed all inflammation in four days. At the termination of a week, I again introduced the needle into the left eye, and attempted to open the capsule by a perpendicular movement of the instrument; but finding that I had detached the lens from the ciliary processes, I withdrew its point, then carried it forward through the anterior chamber, and turning its edge backwards I cut the lens in several pieces; when, to my surprise, the fragments sunk in the vitreous humour so entirely out of the axis of vision, that the man could see minute objects immediately after the operation. No inflammation followed, and he was discharged a fortnight after his admission, able to read the smallest print with his left eye, the pupil of which was perfectly circular, clear, and readily adapting itself to different degrees of light. The half of the lens placed in the anterior chamber of the right eye was not much wasted, but it had assumed a flocculent appearance. I have since

been informed, that in less than two months after his return home, he could see as well with this eye as with the other.*

XXXV.

Jacob Phelps, a young man of Totness, Devon, was admitted an in-patient of the West-of-England Eye Infirmary, for congenital cataracts, July 25th, 1810. In the right eye he had a slate-coloured cataract with a transparent edge, which admitted sufficient light to afford him useful vision; in the left, the cataract consisted of an opaque capsule, and

* A short time subsequent to this operation, I operated on a gentleman, 80 years of age, in one of whose eyes the vitreous humour was similarly disorganized. As soon as I had divided the cataract the fragments immediately disappeared, and the patient could read the smallest print in a day or two, which was as soon as the organ could bear the light. In both these instances, as the natural size and hardness of the eye were preserved, I had no reason, previous to the operations, to suppose the vitreous humour had undergone this morbid change.

a small portion of unabsorbed lens: with this eye he could merely distinguish light and colours. July 26th, I operated on both eyes with the two-edged needle. In the right eye I separated the capsule and lens very freely, and brought as many of the fragments as I could, forward into the anterior chamber. In the left eye the cataract was also freely divided, and lodged in the anterior chamber; the anterior part of the capsule, which could not be divided, remaining behind the iris. No inflammation succeeded the operations. In three weeks the divided cataract in the left eye had entirely disappeared, but the anterior part of the capsule still remained undissolved, floating in the vitreous humour immediately behind the pupil. In five weeks the fragments of cataract in the right eye, which had been brought forward, had become absorbed; but those which remained behind the iris were undiminished. I then repeated the operation on both eyes, brought forward the greater part of the softened lens of the right eye into the anterior chamber, and placed the capsule in the same situation in the left. This in a few days again returned through the pupil; three times successively the same circumstance occurred; on a fourth attempt it returned as soon as the needle was

withdrawn from the eye. I therefore determined to make a small puncture through the cornea and extract it,* which I accomplished without difficulty, with a two-edged scalpel and a curved needle. In three days the puncture had healed sufficiently to admit of the eye being left uncovered, when it had assumed the natural appearance, the pupil being perfectly circular, transparent, and sensible to light. But the retina, from want of exercise, was not so sensible to its natural stimulus, as the free power of contraction and dilatation in the pupil previous to the operation had led me to expect. The cataract in the right eye was not dissolved in less than twelve weeks; when, with the assistance of proper glasses, he was able to see with it, as well as if no disease had previously existed. The length of time necessary for the solution of a slate-coloured cataract was particularly marked in this case; for though it was cut into very small pieces, the greater part of which at the two operations were brought into the anterior chamber, yet it was nearly three months in dissol-

* At that time I was not aware that Mr. Gibson was in the habit of practising this operation, as his Treatise on Artificial Pupil, &c. did not appear until nearly six months afterwards.

ving, while the cataract in the other eye disappeared in three weeks, a part of the opaque capsule alone then remaining.

CASE XXXVI.

John Taylor, of Farringdon, near Exeter, aged 72, was admitted an in-patient of the West-of-England Eye Infirmary, March 6th, 1809. He had large and solid cataracts. In the left eye, I placed the undivided lens in the anterior chamber, which was unusually large. I was induced to make this trial of an undivided lens, from a circumstance that occurred a short time before in the Infirmary. A solid lens had accidentally slipped through the pupil of a patient without division, which at the period of Taylor's application was considerably lessened in size, and had not then occasioned either pain or inflammation. In the right eye, however, I cut the whole of the lens in pieces, and lodged it thus divided in the anterior chamber. No inflammation followed the operation in either eye. In six weeks so many of the fragments in the

right were absorbed, that the upper part of the pupil was sufficiently clear for the patient to read print of a moderate size, with the aid of convex glasses. The opaque lens in the left eye was also considerably diminished. In less than ten weeks the pieces of cataract in the right eye being entirely absorbed, and the left eye perfectly free from pain and inflammation, he was allowed to return home. At the end of a month this man's daughter informed me, that her father's eye, in which the nucleus still remained, was become much inflamed and exceedingly painful. I expressed a wish that he should return to the Infirmary, which being complied with, I found the cataract so much lessened, as to leave one quarter of the upper part of the pupil clear. The mechanical friction of the lenticular nucleus against the iris, had, however, excited a great degree of inflammation accompanied by excessive pain, not only in the eye itself, but also in the side of the head and cheek. The temporal artery was opened, leeches, blisters, sedative applications, &c. were by turns applied, but nothing appeared to afford him so much relief as remaining quiet in bed. In a fortnight or three weeks all pain and irritation having subsided, he was discharged.

from the Infirmary; but as soon as he began to use exercise, the painful symptoms again recurred, which were relieved as before, by the patient keeping constantly in bed. It was more than five months from the operation before the nucleus was entirely absorbed; since which, however, he has been free from uneasiness, and sees equally well with both eyes.

CASE XXXVII.

Mr. V——, a surgeon, of Birmingham, about 60 years of age, applied to me at Bath, to perform an operation for cataract in his right eye. I found he laboured under that large and dark-coloured species which, as I previously told him, would require a considerable length of time to dissolve.

About the middle of January, 1811, in presence of his son, who is also a surgeon, I cut up as much of the anterior part of the cataract as was practicable, and placed the fragments in the anterior chamber. Some inflammation followed, which was removed by the usual means. In six weeks the detached pieces being wholly dissolved, I repeated

the operation. The remaining portion of cataract was still, however, too large and dense to warrant my attempting to divide it. I, therefore, sliced off as much of its softened anterior surface, as nearly to fill the anterior chamber. There was no subsequent inflammation of consequence, and the patient being extremely anxious to return home, he did so in a fortnight or three weeks. More than one half of the cataract had dissolved; and the remaining portion being freely exposed to the action of the aqueous humour, I entertained the hope that its solution would be ultimately effected without any other operation. I saw my patient at Birmingham three or four months afterwards. There was but little diminution in the size of the solid nucleus, a small part only of the outer edge of the pupil being clear, by which he could perceive large objects obliquely with tolerable accuracy. Much disappointed by the slow progress of his cure, I proposed to cut the remaining nucleus in pieces. To this Mr. V. at first consented; but after the speculum was fixed, and I was in the act of passing the needle through the coats of the eye, he became so agitated, that, notwithstanding every argument and persuasion were made use of by his two sons and myself, he would not submit to any further operation.

Since my return to London his son informed me by letter, that nine months after the first operation the cataract had not entirely dissolved; and his father, ignorant how long I might be detained in Ireland, had therefore gone to London, where it was successfully extracted.

CASE XXXVIII.

Col. B—, a gentleman in advanced age, consulted me in London, April 1811, on account of total blind in the right eye, and very imperfect vision in the left. From the latter a cataract had been extracted some time before. On examination, I found a portion of capsule remaining which had become opaque, and the small aperture made in its centre did not admit the rays of light sufficiently to afford good vision. As the pupil in each eye was exceedingly small, this remaining portion of capsule, which was situated near the lower margin of the pupil, had escaped observation, and the cause of his imperfect vision in this eye was not ascertained previous to my seeing him. In the right eye there was a cataract of a

very large size, striated, and of an appearance indicating great solidity. I operated on both eyes the same day. In the left I completely removed the remaining part of the opaque capsule, which enabled the pupil to expand freely; and as no inflammation ensued, the patient, with the aid of a convex glass, read small print with fluency, the second morning after the operation. But previous to my coming to London, having promised to fulfil a professional engagement in Ireland in the month of May, I therefore in the right eye only removed a portion of the anterior capsule, and did not attempt to cut in pieces any part of the opaque lens; expecting that, on my return from Dublin, I should find nothing but the solid nucleus remaining, which could then be easily cut in pieces, and placed in the anterior chamber. Some hours after the operation, inflammation came on in this eye. Blood was abstracted both generally and locally, which, with emollient applications, &c. removed the acute symptoms. I was reluctantly obliged to leave London in three weeks. Some irritation in the eye still remained, but it was by no means of a dangerous kind, as the pupil admitted of being kept in a state of dilatation, by a solution of belladonna. On my departure I

left Col. B.— in charge of a professional friend. I heard nothing of my patient until my return from Ireland in December, when he came to London; and I found that the edge of the cataract having first become dissolved, the nucleus had slipped into the anterior chamber, and by its mechanical friction against the iris had for some weeks kept up irritation and uneasiness in the eye, but by no means in so great a degree as I have sometimes witnessed from a similar cause.

I immediately proposed extracting the nucleus through a puncture in the cornea, which was acceded to, and, on the following morning, with a two-edged scalpel I made an opening about two lines in length, a little anterior to the iris. Through this I introduced a small hook, but had no sooner laid hold of the softened nucleus than it broke into several pieces. These I extracted, except about one eighth part, which I left to dissolve, and which in three weeks entirely disappeared. No unpleasant symptom succeeded the operation, and the wound in the cornea soon healed. From the long-continued friction of the cataract against the iris, the eye however remained weak, and morbidly sensible to light. Nothing appeared to relieve this, but the application

of a blister to the temple, or behind the ear; or otherwise stimulating these parts with an embrocation composed of antim: tartar: and equal quantities of ol: olivar: and aq: ammon: pur:—Five times successively these applications relieved the eye in a most striking manner; but notwithstanding my urgent remonstrances at their being as often laid aside, I could never prevail on my patient to continue them for more than a week or ten days at a time, though a very few days after they were discontinued the eye uniformly became as much affected as before. All local applications to the eye which were tried, excepting the vinum opii and cold water, seemed to increase irritation: they were, therefore, with this exception, wholly laid aside. In consequence of continued weakness in the eye, I did not venture to try spectacles till the beginning of March, when the patient could read small print fluently if placed immediately before him, but could not see it distinctly when in a lateral direction. The eye having now gained strength, I was for the first time enabled to examine the pupil in a strong light, and observed that the posterior part of the capsule remained, and had become opaque; but there was a small aperture in the centre, which perfectly explained the cause of

his imperfect vision. I therefore with the curved-pointed needle removed the whole of the opaque capsule, and left the pupil clear. One or two drops of blood were effused in the anterior chamber during the operation, but were absorbed in a few days, and there was no subsequent inflammation. The pupil is nearly circular, and is considerably larger than when I was first consulted; which I consider a very fortunate circumstance, as the sphere of vision consequently must be much increased.*

---

* While I was in Dublin, I operated on this gentleman's brother, who was more than sixty years of age, and laboured under solid cataracts. I sliced off from the anterior portion of the lens in each eye, as much as filled more than half of the anterior chamber with the fragments, which dissolved without his having experienced the smallest degree of inflammation. It was my intention by a second operation to cut the nuclei in pieces; but in four weeks so much of the remaining lens in one eye had become absorbed, that my patient could both read and write, with which he was perfectly satisfied, and declined any further operation.

CASE XXXIX.

April 1810, I was consulted at Bath by Mrs. C—, a lady more than sixty years of age. She had an opaque lens in the right eye, and symptoms of incipient cataract were observable in the left. The cataract in the former was of a light colour and very opaque, the pupil circular, and sensible to light. Her apprehensions of the operation were so great, that she could only be prevailed on to undergo it, after being present when the operation was performed on a gentleman, who assured her the pain was very inconsiderable. The day after this I operated on her in the presence of her son-in-law Mr. E—, Doctor Wilkinson the ingenious author of a Treatise on Galvanism, and several other professional gentlemen. I divided the whole of the cataract and capsule very freely, but suffered them to remain behind the iris. After I had withdrawn both the needle and speculum, the patient inquired when I intended to commence the operation, and would scarcely believe that it had been already executed. The eye was bound up, and she was put to bed. Violent inflammation came on in the course of the afternoon, for which she was

repeatedly bled in the arm, the temporal artery opened, and some dozens of leeches successively applied at intervals: notwithstanding these active measures, it was nearly a month before I considered the eye free from danger. The pupil was now considerably contracted and of an irregular form; but in about seven weeks, when the divided portions of the lens had disappeared, the circular form was again restored, and the patient could see the minutest objects with the assistance of a proper glass. As she still possessed useful vision in the left eye, I did not then recommend any operation. At times previous to my seeing Mrs. C—, she had experienced vertigo, head-ache, flushings of the face, &c.; which, with a very hard pulse, strongly indicated a disposition to apoplexy, for which she had lost blood, but not in sufficient quantity. The inflammation that succeeded the operation, may therefore be regarded as a fortunate circumstance, as it led to such active depletion, that I have been informed she has since enjoyed much better health and spirits than she did before, and has remained entirely free from those alarming symptoms.

CASE XL.

Ann Shea, aged 64, applied to me in Dublin, May 1811, and stated she had been blind for five years. She had large and solid cataracts, which appeared striated. June 1st, I operated on both eyes, in the presence of several of the most respectable surgeons in Dublin. With my one-edged knife I cut in pieces, very freely, the anterior portion of the capsule and cataract in each eye, and placed the fragments in the anterior chamber. A slight inflammation ensued, which was quickly removed by once bleeding in the arm, emollient applications, &c. In less than a month all the pieces in the anterior chamber were disolved. The patient then went home, and I did not again see her till the middle of August, when on her return to Dublin I found the remainder of the cataracts were but very little diminished in bulk, but they had assumed a lighter colour. I repeated the operation in the presence of Stewart Bruce, Esq. of Dublin Castle, and with the double-edged needle divided into several parts the nucleus in each eye, all of which I brought forward into the anterior chambers. There was no

subsequent inflammation. The absorption of the opaque lenses commenced in a few days, and proceeded so rapidly, that in a fortnight the pupil of the left eye was quite clear, and that of the right nearly so. She could then see to read the smallest print with glasses, and returned home happy and grateful for the benefit obtained.

CASE XLI.

John Herbert, a postillion, Grosvenor Mews, Bond-street, aged 40, applied to me the beginning of December, 1811. He had large and solid cataracts in both eyes; and stated, that in the left he had been blind nearly nine years; that in the right, though his sight had been gradually declining for the last four years, he was able to continue his employment till the preceding summer, when he had been forced to give it up altogether. December 10, 1811, he underwent the operation in both eyes, in the presence of Mr. Sharp, one of the Governors of the London Eye Infirmary. In the left eye I divided the capsule and cataract into three or four parts, and placed the whole in the anterior chamber. A small

part of the pupil, which was perfectly clear, could be seen through an aperture left by two of the pieces of the cataract overlapping, which enabled him immediately to distinguish objects. In the right eye I cut the cataract in halves; one of these I placed in the anterior chamber, and suffered the other to remain behind the iris. There was no inflammation in the left eye during the patient's convalescence, but the right was attacked very severely in the evening. Its progress, however, was arrested by twice copiously bleeding him from the arm. Five days after the operation he had recovered sufficiently to come to my house. In the left eye, for the first fortnight, there was little change in the appearance of the cataract; it then assumed a flocculent appearance, and in another week had diminished so much in size, as to leave more than the upper half of the pupil quite clear; when, assisted by cataract spectacles, he could read print of the smallest type. A fortnight afterwards the whole of the opaque lens and its capsule had disappeared, the pupil was clear and circular, and possessed the power of dilatation and contraction, as perfectly as if no disease had previously existed. When the pupil was under the influence of the belladonna, a very small portion of

capsule was perceptible at its lower edge; but the patient's vision was so good, I could not prevail on him to allow me to remove it by another operation. In the right eye, the half of the cataract placed in the anterior chamber, dissolved nearly in as short a time as in the other; but the remaining half, situated behind the iris, did not become entirely absorbed in less than fourteen weeks after the operation, and for the first ten he had not the smallest use of the eye. During the latter part of the solution of the half, in the anterior chamber, inflammation came on a second time, but was very slight; it, however, increased to a much more serious degree after the entire disappearance of that part, and seemed to arise from the unequal pressure of the remainder of the lens against the posterior part of the iris. It was repeatedly necessary to apply blisters to the temple and behind the ear, during the last weeks of his convalescence, with emollient applications to the eye, &c. and to give purgatives almost daily. There was manifested a strong disposition to a contraction of the pupil, which, however, was overcome by a solution of the extract of belladonna, frequently applied. After the entire disappearance of the cataract, the cornea, which had been previously partially opaque, was

restored to its natural appearance, and the pupil was circular and moveable. A small portion of capsule was still discernible when the pupil was much expanded. But, the patient having returned to his employment as a postillion, no further operation has been thought of, as his vision in this eye is equally as good as in the other. I have been recently informed, that his sight has improved so much, that he has altogether laid aside the use of those glasses which enabled him to see distant objects.

CASE XLII.

In the beginning of March, 1812, I was consulted by Mrs. H——, aged 40, wife to Captain H——, of the 15th Light Dragoons. She laboured under solid cataracts; but they had not reached so advanced a stage, as to preclude her seeing large objects, &c. Her eyes were naturally prominent, with a large anterior chamber, and had been for some years subject to a chronic inflammation, which

rendered them very irritable and sore to the touch. The cataract in the right eye was the most advanced, and was therefore selected for operation. The middle of March, in the presence of Mr. Skirrow, of Gower-Street, I cut in halves the lens and anterior part of the capsule; these I placed, without any further division, in the anterior chamber, as the solidity and large size of the former body prevented my separating it into small portions. The two halves of the cataract so entirely filled the anterior chamber that there appeared no space left for the aqueous humour. No acute inflammation ensued. In a few days, from the continued application of a refrigerent lotion, the patient experienced a rheumatic pain in the cheek and temple, which was also communicated to the eye; but she was relieved by emollients, and the application of four leeches to the corner of the nose and eye-lids. In a fortnight the extremity of the edge of the opaque lens having wasted, the ciliary margin of the iris was perceptible; but in the centre, where the two pieces were kept in close contact, there was little change. In another week its diminution was very visible, and proceeded so rapidly that in little more than five weeks from the operation, the whole of the lens and anterior capsule, which had been also

placed in the anterior chamber, were entirely dissolved. The posterior part, however, of the capsule was opaque, and remained in its natural situation. There was an aperture in its centre, which admitted sufficient light to enable the patient to read the smallest print, when placed immediately before the eye, with the assistance of a convex glass; but the extent of vision was very limited. At this period Mrs. H. was unexpectedly called into the country; and on her return to town, I intend removing the remaining portion of capsule; by which her sphere of vision will be considerably increased.

CASE XLIII.

Charles J——n, Esq. of Lancing, Sussex, aged 36, was born deaf, and consequently never acquired the perfect powers of speech. He was placed at an early age under the tuition of the celebrated Abbé de l'Epée at Paris, who taught him a guttural utterance, which was intelligible to those accustomed to be with him. Reading being his only amusement, he

was well acquainted with most authors, and his disposition was so placid and contented, he appeared happy without any other resource. At the age of eighteen he was however attacked with a dimness of vision, which progressively increased for five years, when he became incapable of reading, or of discerning any minute objects. Flashes of red and white light now appeared, occasionally changing to dark motes, and black streaks, which almost constantly flitted before his eyes. His mind, naturally active and intelligent, then sunk into despondence, and from a want of sufficient bodily exercise, he in a few years became so plethoric that an apoplectic tendency was strongly manifest. About seven years ago he became very lethargic, the scalp œdematous, and he was attacked occasionally with vertigo. Mr. Ware was consulted, who judiciously ordered setons to the temples, and an issue in the back of the neck, which carried off the increased size of the scalp, but, as I was informed by Mr. J.'s mother, he declined attempting any operation to restore sight, considering the case confirmed gutta serena. From this period all hopes of cure by an operation were given up, until Mr. J—n was brought to me the beginning of April 1812, when

I discovered an opacity deeply seated in the vitreous humour. The pupils possessed their natural sensibility, and he could perceive the outlines of objects. The light had formerly seemed to him of a yellow colour in both eyes, but since the application of a stimulant drop, prescribed by a celebrated empiric some time previous to my seeing him, it had changed to a purple colour in the left. The opacity at the first view appeared as if seated in the retina, but on attentively examining the eyes after the pupils had been dilated by the belladonna, it was evidently in the posterior part of each capsule, the centre of which in both eyes was more diseased than the circumference. The anterior part of the capsules and the lens were perfectly transparent. Although the black spots, flashes of light, &c. proved that the retina was diseased, yet considering it more as a functional than an organic defect arising from a want of due exercise of the organ, I conceived, if the obstacle to the passage of light could be removed, the patient might obtain useful vision. April the 16th, in the left eye (which was by far the most diseased), I divided the anterior capsule and lens into three or four parts, and brought them forward

into the anterior chamber, the whole of which they occupied. No acute inflammation succeeded, but some redness continuing in the conjunctiva for some time, though unattended with pain or intolerance of light, I ordered leeches to the eye-lids twice or thrice at intervals of some days. The second or third day after the operation the lens had become opaque; in ten days, absorption had commenced, and proceeded so rapidly, that in less than a month the whole of the lens and anterior capsule were dissolved. The posterior capsule however remaining, May 25th I removed it by a second operation, and left the pupil perfectly clear and circular. May 27th, the patient could mark the time by a watch, and on the 5th of June, when this case was taken down, he read print of a moderate size without any difficulty, and, assisted by a convex glass of three inches and a half focus, told the hour by a church clock at a considerable distance. He then returned home. June 22d I received a letter from Mrs. J—n, informing me her son "with his spectacles now reads with great facility, and sees every object; the motes begin to disappear, but he still sees fifteen candles where there are but two, unless he puts on his spec-

tacles, when the number appears as they really are."*

To this letter Mr. J——n himself added a line, expressive of his happiness and gratitude.

---

* About two years since I successfully operated for cataract on Mr. Williams, a gentleman concerned in an extensive Brewery at Bath, who for more than twenty years had been blind as was supposed from amaurosis. During this period he several times went to London to obtain the best advice; but as he had symptoms very similar to those under which Mr. J—n laboured when I was first consulted, no operation had been considered advisable. After the removal of the cataract, Mr. W. also saw a great number of candles instead of one; every thing for some time appeared by day of a green colour; and at night the sky seemed as if on fire. These symptoms certainly bespoke that the retina was functionally deranged; they however decreased in proportion as the eye was exercised, until they entirely disappeared, and he now sees as well as any patient on whom I have ever operated for cataract.

POSTSCRIPT.

Observations on some Symptoms generally considered indicative of Amaurosis.

In my general observations on the operations for obliterated pupil, I have remarked that it was sometimes very difficult previously to ascertain the real state of the retina in that disease, as I had often experienced success from the operation when I least expected it, and had been disappointed when the symptoms appeared favourable. The same uncertainty exists in cases of cataract, when uncombined with adhesions between the iris and capsule of the lens. The state of the pupil as to its size and powers of motion, and the appearance of muscæ volitantes, have been generally considered by authors who have written on diseases of the retina, as the principal symptoms for ascertaining its actual state; but experience has convinced me, that the inference, though frequently correct, is not conclusive. In the commencement of my practice, confiding in the exactness of the observations of my predecessors,

I was deterred from making any attempt to relieve a patient by an operation under such circumstances; but I have in many instances since succeeded when these symptoms have been present, and on the contrary have sometimes failed, when from the mobility of the pupil I had reason to expect success. I have seen amaurosis exist when the pupils were not only of a natural size, but even evinced considerable mobility when exposed to different degrees of light. In other cases, though the pupil has remained dilated and fixed after the operation for cataract, yet the patients obtained as perfect vision as is ever enjoyed after the removal of the opaque crystalline. There are also instances of a considerable enlargement of the pupil without any attendant injury to vision, and uncombined with any other disease. Where adhesions between the capsule and iris are complete, this morbid state is readily ascertained by the irregular form of the pupil, and its incapability of motion when the eye is exposed to different degrees of light, or after the extract of belladonna has been applied; but if the adhesions are confined to the circumference of the capsule, the circular form of the pupil is preserved, and there is a slight degree of motion perceptible in the pupil; though in both cases the

retina is equally sound. It is evident from all these facts, that neither the size of the pupil, nor the functions of the iris, can lead with precision to the state of the retina. But what renders the symptoms of amaurosis still more uncertain is, that the flashes of red and white light, black spots, streaks, flies, &c. floating before the eyes, which have been generally considered diagnostic of amaurosis, are proved not to be so by Case 43. In three or four other instances, where I have recently operated with success, this truth is further confirmed. One of these, is in a gentleman who has laboured under a dark-coloured cataract for the last twelve years. During this period he three times came from Ireland to London for advice, but from the presence of these symptoms, the case was considered, and treated, as amaurosis, and he was not aware that he had a cataract until he consulted me. The same opinions had been entertained in the case of another of my patients; a gentleman residing in London, in whom the opacity was confined to the posterior capsule, as in Case 43, where it had existed for seven years, and the real nature of the disease had not been suspected. I have also within the last month operated for cataract on a fourth patient, who has

been blind nearly twenty years, and, labouring under very similar symptoms, was likewise considered as incurable. He is already able to discern minute objects, and as the powers of the retina daily increase, there is every reason to hope for ultimate success. I am therefore persuaded, that the cataract should always be removed, when the patient can discern light from darkness, and the shadow of the hand passed between the light and the eyes. Although I would by no means venture to predict uniform success in such cases, yet the benefit to be obtained is so great, that I think the trial ought to be made; particularly as, from the mildness of the operation, the attendant pain is very trifling, and there is little if any risk of producing deformity.

FINIS.

J. Brettell, Printer, Rupert-Street,
Haymarket, London.

ERRATA.

Page 18, line 5, *for* to prevent the ligature from ulcerating, *read* to prevent the ligature from causing ulceration.
—— 33, —— 14, *for* it is termed, *read* it may be termed.
—— 35, —— 5, *for* to any other author, *read* to any author.
—— 43, —— 19, *read* could not see *sufficiently* to avoid, &c.
—— 47, —— 22, and page 48, line 1, *for* pursuing this plan first recommended, *read* pursuing the plan just recommended.
—— 54, —— 3, *for* or, *read* nor ; line 19, *for* agglutenates, *read* agglutinates.
—— 58, —— 21, *for* to avoid objects sideways, *read* to avoid objects which presented themselves sideways
—— 60, —— 2 and 3, *for* this complicated state of disease, *read* these complicated states of disease.
—— 61, —— 15, *for* in *read* to.
—— 81, —— 16, *read* perfectly.
—— 113, note line 2, *for* Shelden *read* Sheldon.
—— 120, line 22, *for* curvette, *read* curette
—— 121, —— 1, *for* parts *read* part
—— 160, —— 3, *read* pieces
—— 194, —— 3, *read* I. Weld, Esq.
—— 212, —— 15, *read* St. Guineas, Cornwall.
—— 231, —— 9, *read* blindness.
—— 238, —— 13, *read* dissolved.

Plate 2

1

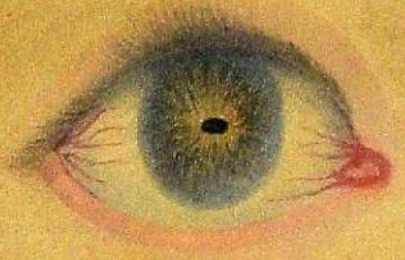

2

1 *The Pupil in John Mercers right eye previous to the last operation.*

2 *Represents the subsequent appearance.*

Engraved by J. Hawksworth

Published May 28th 1812, by Callow, Crown Court.

Plate 3.



Engraved by J. Hawksworth.

Published May 28th 1812, by Callow, Crown Court.

MEDICAL BOOKS

PUBLISHED BY

J. CALLOW, MEDICAL BOOKSELLER,

10,

CROWN-COURT, PRINCES-STREET,

SOHO;

WHO EITHER GIVES THE FULL VALUE FOR SECONDHAND MEDICAL BOOKS, OR EXCHANGES THEM.

ANNUAL (The) MEDICAL REVIEW and REGISTER, for 1808: comprising a critical Account of every Publication relating to Medicine and Surgery, which appeared during that year; together with an Historical Sketch of the Discoveries and Improvements in these and the collateral Sciences within the same Period; a Report of the general State of Health and Disease in the Metropolis, &c. By a Society of Physicians. Handsomely printed in 8vo. vol. 1, boards, 7s, 1809

The same for the year 1809, vol. 2, 8vo. boards, 8s, 1810

ADAMS's (Dr. Joseph) GUIDE to MADEIRA; containing a short Account of Funchall, with Instructions to such as repair to the Island for Health, 2d edition, price 1s 6d

ADAMS's (Dr. Jos.) OBSERVATIONS on the CANCEROUS BREAST; consisting chiefly of original correspondence between the Author and Dr. Baillie, Mr. Cline, Dr. Babington, Mr. Abernethy, and Dr. Stokes; published by permission of the Writers; with an Introductory Letter to Mr. Pitcairn; 8vo. boards, 4s

ADAMS's (Dr. Jos.) OBSERVATIONS on MORBID POISONS in two Parts: Part I. containing Syphilis, Yaws, Sivvens, Elephantiasis, and the Anomala confounded with them.—Part II. On Acute Contagions, particularly the Variolous and Vaccine. Second edition, illustrated with four coloured engravings, copious practical Re-

marks, and further Commentaries on Mr. Hunter's Opinions, by Joseph Adams, M.D. F.L.S. Physician to the Small Pox and Inoculation Hospitals, in one large 4to. boards, 1l 5s.

"Some judicious remarks on Variolus and Vaccine Inoculation terminate this work; which must be considered as far superior to the ephemeral productions of authors, who want to write themselves into a high road to riches and renown. This volume is valuable in another point of view, because it inculcates the habit of analysing diseases, and shews the importance of minute attention in tracing the history and progress of every series of morbid action."—*Vide Edinburgh Journal, vol.* iii.

ADAMS's (Dr. Joseph) INQUIRY into the LAWS of EPIDEMICS, with Remarks on the Plans lately proposed for exterminating the Small-Pox, by Jos. Adams, M.D. F.L.S. boards, 5s 6d, 1810

AITKIN's (Dr. John) ESSAYS on FRACTURES and LUXATIONS, 8vo. plates, boards, 4s, 1800

ANDREW's OBSERVATIONS on the Application of Lunar Caustic to Strictures in the Urethra and the Œsophagus: illustrated by Cases, and with plates, by M. W. Andrews, M. D. Member of the Royal College of Surgeons, London, and now Physician at Madeira; 8vo. boards, price 5s 6d

BURNS' (Allan) OBSERVATIONS on the SURGICAL ANATOMY of the HEAD and NECK, 8vo. 10 engravings, 12s. bds.

BELL's (John) DISCOURSES on the NATURE and CURE of WOUNDS, 8vo. 3rd edition, revised and corrected, with plates, 12s. in boards.

BARCLAY's (Dr. John) DESCRIPTION of the ARTERIES, with copious notes, 12mo.

In this description, the Ramifications, belonging to the Species, are carefully distinguished from those that characterise only Individuals; and where there are exceptions from the general rules, those are regularly explained in the Notes.

BARCLAY's MUSCULAR MOTIONS of the HUMAN BODY, 8vo. 10s. 6d. in boards.

BADHAM's OBSERVATIONS on the Inflammatory Affections of the Mucous Membrane of the Bronchiæ, comprehending an account of the Acute Inflammation of the Parts, of Peripneumonia Notha, and of Chronic Coughs, &c. by Charles Badham, M. D. Lecturer on the Practice of Physic, &c. and late Physician to the Westminster General Dispensary, boards, 4s, 12mo.

BOYER's LECTURES on DISEASES of the BONES, arranged into a systematic Treatise, by A. Richerand, Professor of Anatomy and Philosophy, and Surgeon to the Northern Hospital at Paris: translated from the French by M. Farrell, M.D. 2 vols. plates, boards, 10s, 1810

BOSTOCK's REMARKS on the NOMENCLATURE of the New London Pharmacopœia, read before the Liverpool Medical Society, by John Bostock, M.D. 2s 6d, 8vo. 1810

BREE's PRACTICAL INQUIRY into DISORDERED RESPIRATION; distinguishing the Species of Convulsive Asthma, their Causes, and Indications of Cure, by Robert Bree, M.D. F.R.S. Fellow of the Royal College of Physicians: the 4th edition, with additional practical Observations; in 8vo. price 8s, boards

BUTTER's (Dr. William) ACCOUNT of PUERPERAL FEVERS, as they appeared in Derbyshire and some of the Counties adjacent, illustrated by Cases and successful Methods both of Prevention and Cure, 2s 6d

BUTTER on the INFANTILE REMITTENT FEVER, commonly called the Worm Fever: accurately describing that fatal Disease, explaining its Causes and Nature, and discovering an easy, safe, and successful Method of Cure, 2d edition, 1s 6d

BUTTER's (Dr. William) IMPROVED METHOD of OPENING ARTERIES. Also, a new operation for extracting the Cataract. With Cases and Operations, illustrating the good Effects of Arteriotomy, Hemlock, and other remedies in various Diseases, 4s

BUTTER's Dr. William) TREATISE on the ANGINA PECTORIS, 2s

BUTTER's (Wm.) TREATISE on the VENEREAL ROSE, commonly termed the Gonorrhœa Virulenta, containing a simple, safe, and certain Method of Cure, without the Use of Mercury, 2s 6d

CLARK's (Jn.) OBSERVATIONS on the Diseases which prevail on Long Voyages to Hot Countries, particularly to the East Indies; and on the same Diseases as they appear in Great Britain, 8vo. boards, 7s 6d, 1809.

CURSORY REMARKS on CORPULENCE. By a Member of the Royal College of Surgeons, sewed, 2s, 8vo.

> Think not, ye Candidates for health,
> That ought can gain the wish'd for prize,
> (Or pill or portion, power or wealth,)
> But temperance and exercise.

CARMICHAEL's (R.) ESSAY on the Nature of SCROFULA, with Evidence of its Origin from Disorders of the Digestive Organs; illustrated by a number of Cases, successfully treated, and interspersed with Observations on the General Treatment of Children, 8vo. boards, 5s

CARMICHAEL's ESSAY on the Effect of CARBONATE and other Preparations of IRON UPON CANCER; with an Inquiry into the Nature of that and other Diseases, to which it bears a relation. By Richard Carmichael, Surgeon, 2d edit. considerably enlarged and improved, boards, 10s 6d, 8vo.

CUTHBERTSON's PRACTICAL TREATISE on ELECTRICITY and GALVANISM, by John Cuthbertson, Philosophical Instrument Maker, and Member of the Philosophical Societies of Holland and Utrecht, illustrated with nine copper-plates, boards, 10s 6d

CRICHTON's (Dr. Alex.) SYNOPTICAL TABLE of DISEASES, exhibiting their arrangement in Classes, Orders, Genera and Species, designed for the use of Students, on 2 sheets, imperial fol. 2s 6d

COPELAND's (Thos.) OBSERVATIONS on some of the principal DISEASES of the RECTUM and ANUS; particularly Stricture of the Rectum, the Hæmorrhoidal Excrescence, and Fistula in Ano, boards, 5s, 8vo. 1810

CROWTHER's PRACTICAL OBSERVATIONS on the DISEASE of the JOINTS, commonly called White Swelling; with some Remarks on Caries, Necrosis, and Scrophulous Abscesses; in which a new and successful Method of treating these Diseases is pointed out, Second edition, with considerable additions and improvements. By Bryan Crowther, Member of the Royal College of Surgeons in London, and Surgeon to Bridewell and Bethlem Hospitals. illustrated with seven coloured plates, 10s 6d, boards,—ditto, large paper, with proof impressions of the plates, 16s

CABANIS' (P. J. G.) SKETCH of the REVOLUTIONS of MEDICAL SCIENCE, and Views relating to its Reform; translated from the French, with notes; by A. Henderson, M.D. 8vo. boards, 9s

CURTIS' (Charles) ACCOUNT of the DISEASES of INDIA, as they appeared in the English Fleet, and in the Naval Hospital at Madras, in 1782 and 1783; with Observations on Ulcers, and the Hospital Sores of that Country, &c. &c. to which is prefixed a View of the Diseases on an Expedition and Passage of a Fleet and Armament to India in 1781, 8vo. boards, 7s

A. CORN. CELSI DE MEDICINA Libri Octo quibus accedunt, Indices Capitum Autorum et Rerum ex Recensio Leonardi Targæe. In 8vo. boards, 12s

COOPER's (Sam.) CRITICAL REFLECTIONS on several Important Practical Points relative to the Cataract, 8vo. boards, 5s.

COOPER's (Samuel) TREATISE on the DISEASES of the JOINTS; being the Observations for which the Prize for 1806 was adjudged by the Royal College of Surgeons in London, 8vo. boards, 5s

COUPER's SPECULATIONS on the MODE and APPEARANCES of IMPREGNATION in the HUMAN FEMALE; with an Account of the principal Ancient, and an Examination of the Modern Theories of Generation, 3d edit. with considerable additions, 4s.

CASES of the EXCISION of CARIOUS JOINTS, by H. Park, Surgeon in the Liverpool Hospital; and P. F. Moreau, De Bar-sur-Ornain.

M. D. de l'Ecole de Paris; with Observations by James Jeffray, M. D. Professor of Anatomy and Surgery in the College of Glasgow. Illustrated by engravings, 12mo. boards, 4s 6d.

DUFOUR's TREATISE on DISEASES of the URETHRA, particularly describing the various Symptoms attending Strictures, Obstructions, Gleets, &c. and on the Prevention of Stone and Gravel, with a variety of Cases, tending to shew the efficacy of Daran's Medicated Bougies, and a new Method of treating a Gonorrhœa, &c. 7th edition, 3s.

DAVIS' (Dr. J. B.) SCIENTIFIC and POPULAR VIEW of the FEVER of WALCHEREN, and its Consequences, as they appeared in the British Troops returned from the late Expedition—with an Account of the Morbid Anatomy of the Body, and the Efficacy of Drastic Purges and Mercury in the treatment of this Disease, 8vo. boards, 7s.

DAUBENTON's OBSERVATIONS on INDIGESTION, in which is satisfactorily shewn the Efficacy of Ipecacuanha, in relieving this, as well as its connected Train of Complaints peculiar to the Decline of Life; translated from the French, 3d edition, with additions, by Dr. Buchan, 1s 6d.

DOMEIER's (Wm.) OBSERVATIONS on the Climate, Manners an Amusements of MALTA, principally intended for the information of Invalids repairing to that Island for recovery of Health; by William Domeier, M. D. of the Royal College of Physicians, London, boards, 4s 6d, 1810.

EARLE's (Sir James) LETTER, containing some Observations on the Fractures of the Lower Limbs; to which is added, an Account of a Contrivance to administer Cleanliness and Comfort to the Bed-ridden, or Persons confined to Bed by Age, Accident, Sickness, or any other Infirmity, with Explanatory Plates, sewed, 3s.

EARLE's (Sir James) OBSERVATIONS on HÆMORRHOIDAL EXCRESSENCES, second edition, sewed, 1s 6d

ESTE's (M. L.) CURSORY REMARKS on Contagious Diseases, and on Baths, 2 parts, 8vo. sewed, 4s 6d

ESTE's (M.L.) LETTER concerning the Royal and other Scientific Institutions: respectfully addressed to their Managers, Proprietors, and Subscribers, containing his Prospectus for the introduction of a particular branch of Science, his Correspondence, together with some general Remarks upon the Management of Scientific Institutions, 8vo. 1s 6d

FORD's OBSERVATIONS on the Disease of the HIP JOINT; to which is added, some remarks on White Swellings of the Knee, the Caries of the Joint of the Wrist, and other similar Complaints. The whole illustrated by Cases and Engravings taken from the Diseased Part, by the late Edward Ford, Esq. F.S.A. The 2d edition, revised carefully, with some additional Observations, by Thomas Copeland, Fellow of the College of Surgeons, and Assistant Surgeon to the Westminster General Dispensary. Illustrated with 8 copper-plates, 8vo. boards, 12s, 1810.

FOX's (Dr. Jos.) NEW MEDICAL DICTIONARY, containing a concise explanation of all the Terms used in Medicine, Surgery, Pharmacy,.Botany, Natural History and Chemistry; compiled by Dr. J. Fox; revised and augmented by Dr. Thomas Bradley, 12mo. boards, 7s.

GRIFFITH's (Dr. Moses) PRACTICAL OBSERVATIONS on the Cure of Hectic and Slow Fevers and the Pulmonary Consumption; to which is added, a Method of treating several Kinds of Internal Hæmorrhages, a new edition, sewed, 1s 6d

GIRDLESTONE (Dr. Thos.) on DIABETES, with an Historical Sketch of that Disease, sewed, 2s 6d, 8vo.

GORDON's (Dr. Alex.) TREATISE on the Epidemic Puerperal Fever of Aberdeen, sewed, 2s 6d

GEOGHEGAN's COMMENTARY on the Treatment of Ruptures, particularly in a State of Strangulation; by Edward Geoghegan, Member of the College of Surgeons, and Honorary Member of the Royal Medical Society, Edinburgh, 8vo. boards, 4s, 1810 —"This work will be found highly interesting, as it proposes important improvements in the treatment."

GOURLAY's OBSERVATIONS on the Natural History, Climate, and Diseases of MADEIRA, during a Period of Eighteen

Years; by William Gourlay, M.D. Fellow of the Royal College of Physicians, Edinburgh; and Physician to the British Factory of Madeira, 8vo. boards, 6s, 1810.

GRAVES's CONSPECTUS of the London, Edinburgh, and Dublin Pharmacopœias; wherein the Virtues, Uses, and Doses of the several Articles and Preparations contained in those Works are concisely stated; their Pronunciation, as to Quantity, is correctly marked; and a variety of other Particulars respecting them given; calculated more especially for the use of Junior Practitioners: by Robert Graves, M. D. 18mo. 4s 6d

GILLMAN's (James) DISSERTATION on the BITE of a RABID ANIMAL; being the Substance of an Essay which received a Prize from the Royal College of Surgeons in London, in the year 1811; 8vo. bds. 7s.

HARTY's (Dr.) OBSERVATIONS on the SIMPLE DYSENTERY, and its Combinations; containing a Review of the most celebrated Authors who have written on this subject, and also an Investigation into the source of Contagion in that and some other Diseases, boards, 7s 6d, 8vo.

"This Work we find no difficulty in recommending to our Readers: it contains, unquestionably, a larger mass of evidence than is any where else to be found of the various species of this formidable disease; and again we think it right once more to recommend the Work before us, as the most valuable digest of all that has been written upon it."—*Vide Medical and Physical Journal, for December*, 1805.

"We have derived much gratification from the perusal of this volume, since, without going the complete length of all his speculations, we think that the Author has manifested a considerable share of ability in their support; he merits the praise of sagacity, for the selection and arrangement of his materials; of great industry in the collection of them; and of having manifested a becoming modesty in the enunciation of his own conjectures."—*Vide Monthly Review, for June*, 1806.

HUNTER's (Jn.) TREATISE on the VENEREAL DISEASE, with an Introduction and Commentary, by Dr. Joseph Adams, boards, 14s, 8vo.

HIGGIN's (William) ESSAY on the THEORY and PRACTICE of BLEACHING, wherein the Sulphuret of Lime is recommended as a Substitute for Potash, sewed, 2s.

HASLAM's (John) OBSERVATIONS on MADNESS and MELANCHOLY, including Practical Remarks on those Diseases: together with Cases, and an Account of Morbid Appearances on Dissection; by John Haslam, late of Pembroke Hall, Cambridge; Member of the Royal College of Surgeons, and Apothecary to Bethlem Hospital, 2d edition, considerably enlarged, in one vol. 8vo. boards, 9s.

HASLAM's (John) ILLUSTRATIONS of MADNESS: exhibiting a singular Case of Insanity, and a no less remarkable difference in Medical Opinion: developing the Nature of Assailment, and the Manner of Working Events; with a Description of the Tortures experienced by Bomb-bursting, Lobster-cracking, and Lengthening the Brain; illustrated with a curious plate, 8vo. boards, 5s 6d.

HOWARD's (John) Practical Observations on the Natural History and Cure of the Venereal Disease, 2nd edit. in 2 vol. 8vo. plates, boards, 14s.

HAMILTON's OBSERVATIONS on Scrofulous Affections, with Remarks on Schirrhous Cancer, and Rachitis, boards, 3s, 12mo

HOOPER's (Dr. Robert) QUINCY's LEXICON MEDICUM. A new Medical Dictionary; containing an explanation of the Terms in Anatomy, Physiology, Practice of Physic, Materia Medica, Chemistry, Pharmacy, Surgery, Midwifery, and the various branches of Natural Philosophy connected with Medicine. Selected, arranged, and compiled from the best authors, 8vo. boards, 18s.

HUTCHINSON's (Dr. A.C.) LETTER, respectfully addressed to the Commissoners for Transports, Sick and Wounded Seamen, &c. &c. &c. on the subject of the operation for POPLITEAL ANEURISM; illustrated by Cases and a Description of a new Instrument, 8vo. sewed, 1s. 6d. 1811.

" The value of a book is not always to be estimated by its extent: This small pamphlet clearly states practical facts of great importance, and the result of the method of operating for Popliteal Aneurism, employed by Dr. Hutchison, was so compleatly successful in the Cases related, that we cannot recommend it too forcibly to the consideration

of our Chirurgical readers."—*Vide Medical and Physical Journal for September* 1811.

JOHNSON's PRACTICAL ESSAY on CANCER, being the substance of Observations to which the Annual Prize for 1808, was adjudged by the Royal College of Surgeons, London; by Christopher Turner Johnson, Surgeon, of Exeter, Member of the Royal College of Surgeons, London, and of the Royal Medical Society of Edinburgh, 8vo. boards, 5s 6d, 1810.

IDENTITIES ASCERTAINED; or, an Illustration of Mr. Ware's Opinion respecting the sameness of Infection in VENEREAL GONORRHŒA, and OPTHALMIA in Egypt: with an Examination of Affinity between Ancient Leprosy and Lues, 2s 6d, 8vo.

KEATE's (Thomas) CASES of the Hydrocele and Hernia Incarcerara, sewed, 1s 6d

LIND on DISEASES incidental to EUROPEANS in HOT CLIMATES, with the Method of preventing their fatal Consequences; the sixth edition, in one vol. 8vo. price 8s, bds. 1808.

LAWRENCE's (William) TREATISE on RUPTURES, containing an Anatomical Description of each Species; with an Account of its Symptoms, Progress, and Treatment: illustrated with plates. By William Lawrence, Member of the Royal College of Surgeons, and Demonstrator of Anatomy at St. Bartholomew's Hospital; in large 8vo. 10s 6d, boards, 1810.

LIPSCOMB's MANUAL of INOCULATION, for the Use of the Faculty and Private Families; pointing out the most approved Method of Inoculating and conducting Patients through the Small Pox, sewed, 1s.

LONDON DISSECTOR; or, System of Dissections practised in the Hospitals and Lecture Rooms of the Metropolis: explained by the clearest Rules, for the Use of the Students. Comprising a Description of the Muscles, Vessels, Nerves, and Viscera of the Human Body, as they appear on Dissection, with Directions for their demonstration; third edition, 12mo. 5s

LONDON PRACTICE of MIDWIFERY, or a Manual for Students, being a complete Course of Practical Midwifery, in which are

included the Treatment of Lying-in Women, and the Diseases of Children, the third edition corrected, 12mo. boards, 6s.

LUXMORE's FAMILIAR OBSERVATIONS on RUPTURES, for the Use of Patients of both Sexes, afflicted with those Complaints; second edition, price 2s.

LONDON (The) MEDICAL DICTIONARY; including under distinct heads every branch of Medicine, viz. Anatomy, Physiology, and Pathology, the Practice of Physic and Surgery, Therapeutics, and Materia Medica; with whatever relates to Medicine in Natural Philosophy, Chemistry, and Natural History. By Bartholomew Parr, M.D. The whole illustrated with 57 highly finished Engravings, 3 vol. 4to, boards, 6l.

MEDICAL FACTS and OBSERVATIONS, consisting principally of Original Communications from Gentlemen of the Faculty; on important Subjects in Medicine and Surgery, &c. by Dr. Simmons, vol. 8, boards, 5s. 8vo.

MURPHY's NATURAL HISTORY of the HUMAN TEETH; with a Treatise on their Disease from Infancy to Old Age, adapted for general information. To which are added, Observations on the Physiognomy of the Teeth and Projecting Chin. Illustrated with two Engravings. By Joseph Murphy, Surgeon, Dentist, boards, 6s, 8vo.

MEMIS' (John) MIDWIFE'S POCKET COMPANION, a Practical Treatise of Midwifery, on a new Plan, sewed, 1s 6d, 12mo.

MERRIMAN's (Dr. Samuel) DISSERTATION on RETRORERTION of the WOMB; including some Observations on extra Uterine Gestation; 8vo. sewed, 3s

NOTT's (Dr. John) POSOLOGIC COMPANION to the LONDON PHARMACOPŒIA; the third edition, adapted to the last reform of the College, 18mo. sewed, 3s.

NISBET's PRACTICAL TREATISE on DIET, and on the most salutary and agreeable means of supporting Life and Health by Aliment and Regimen, adapted to the various circumstances of Age, Constitution, and Climate, 12mo. boards, 6s.

NISBET's INQUIRY into the History, Nature, Causes, and different Modes of Treatment hitherto pursued in the Cure of SCROFULA, PULMONARY CONSUMPTION, and CANCER; the 2d edition; to which is added, an Appendix, containing a Letter to a celebrated Professor of Edinburgh, 8vo. boards, 5s.

PEARSON's (Jn.) PRACTICAL OBSERVATIONS on CANCEROUS COMPLAINTS, with an account of some Diseases which have been confounded with the Cancer; also Critical Remarks on some of the Operations performed in Cancerous Cases, sewed, 2s 6d, 8vo

PEARSON's PRINCIPLES of SURGERY, for the Use of Chirurgical Students; a new edition with additions. By John Pearson, F.R.S. Senior Surgeon to the Lock Hospital and Asylum, Sugeon to the Public Dispensary, and Reader on the Principles and Practice of Surgery, in one vol. 8vo. boards, 8s 6d

PEARSON's OBSERVATIONS on the effects of various articles of the MATERIA MEDICA, in the Cure of LUES VENEREA, illustrated with Cases. By John Pearson, F.R.S. Senior Surgeon of the Lock Hospital and Asylum, and Senior Surgeon to the Public Dispensary, Reader on the Principles and Practice of Surgery, 2d edition, with additions, 7s, 8vo.

POTT's CHIRURGICAL WORKS, 3 vol. 8vo. new, boards, 18s, 1783—N.B. This is the last edition published by the author.

POTT's CHIRURGICAL WORKS, a new Edition, with his last Corrections; to which are added, a short Account of the Life of the Author, a Method of curing the Hydrocele by injection, and occasional Notes and Observations, by Sir James Earle, F.R.S. Surgeon Extraordinary to the King, &c. 3 vol. boards, 1l 7s, 1808

ROYSTON's (W.) OBSERVATIONS on the RISE and PROGRESS of the MEDICAL ART in the British Empire; containing Remarks on Medical Literature, and a View of a Bibliographia Medicinæ Britannicæ, 2s.

PAUL on ARTIFICIAL MINERAL WATERS, sewed, 2s.

REES' (Dr. George) TREATISE on DISEASES of the UTERUS; in which are included Remarks on Moles, Polypi, and Prolapsus, as also on Scirrhous and Cancerous Affections of that Organ, boards, 4s 6d, 8vo.

REES' (Dr. George) TREATISE on the PRIMARY SYMPTOMS of the LUES VENEREA, with a concise, critical, and chronological Account of all the English Writers on this Subject, from 1735 to 1783; to which is added, an Analysis of a Course of Lectures delivered by the Author, boards, 5s, 8vo.

ROLLO's CASES of the DIABETES MELLITUS, with the Results of the Trials of certain Acids and other Substances in the Cure of the Lues Venera, 2d edition, with large additions, boards, 6s, 8vo.

RICHTER's (A. G.) MEDICAL and SURGICAL OBSERVATIONS, 8vo. 5s.

RYDING's VETERINARY PATHOLOGY, or a Treatise on the Cure and Progress of the Disease of the Horse, &c. &c. and an Appendix, or Veterinary Dispensatory, &c. boards, 3s 6d, 8vo.

RING's (John) TREATISE on the GOUT; containing the Opinions of the most celebrated Ancient and Modern Physicians in that Disease; and Observations on the Eau Medicinale, 8vo. boards, 6s.

RUSSELL's (Dr.P.) TREATISE on the PLAGUE: containing an Historical Journal, and Medical Account of the Plague, at Aleppo, in the year 1760, 1761, and 1762; also Remarks on Gurantines, Lazarettos, and the Administration of Police in Times of Pestilence; to which is added an Appendix, containing Cases of the Plague; and an Account of the Weather during the pestilential Season, 4to. bds. 15s.

SMITH's (S.S) ESSAY on the Causes of the Variety of Complexion and Figure in the Human Species; to which are added, Strictures

on Lord Kaimes's Discourse of the Original Diversity of Mankind, a new edition, with additional notes, boards, 4s

SYNOPSIS PHARMACOPŒIÆ LONDINENSIS ALPHABETICA; omnia ejus Præparat complectens, secundum eorum vires medicas vel enemicas; ostendens eorum Doses; nomina priora; Rationem qua Antimonium, Arsenicum, Carthartica, Emetica, Hydrargyrus, et Opium, in quibusdam compositis continenter: quantitatem medicaminum vegetabilium in Decoctis, Infusis, et Tincturis: item quantum Salium singulorum liquatur in aqua ad ejus saturationem; by a Physician, sewed, 1s 6d

SKELLET's (E.) PRACTICAL TREATISE on the Parturition of the Cow, or the Extraction of the Calf; and also on the Diseases of neat Cattle in general, with their most approved Methods of Treatment, and the best forms of Prescriptions adapted to Veterinary Practice; to which is added, an Account of the Diseases of the Bullock, Bull, and Calf. Illustrated with engravings, 4to. half-bound, 2l 2s

TUOMY's TREATISE on the PRINCIPAL DISEASES of DUBLIN; by Martin Tuomy, M. D. T.C.D. in 8vo. boards, 10s 6d, 1810.

TRYE's ESSAY on some of the STAGES of the OPERATION of CUTTING for the STONE; illustrated with an Engraving; by C. B. Trye, F.R.S. 8vo. sewed, 2s.

UNDERWOOD's (Dr. M.) TREATISE on DISORDERS of CHILDHOOD, and Management of Children from the Birth, adapted to Domestic Use; 2d edition, 3 vol. boards, 12mo. 12s.

UNDERWOOD's (Dr. M.) TREATISE on the DISEASES of CHILDREN, with Directions for the Management of Infants from the Birth, and now precisely adapted to professional Readers; 6th edition, revised and enlarged, 3 vol. boards, 15s, 8vo.

UNDERWOOD's SURGICAL TRACTS, containing a Treatise on Ulcers of the Legs, in which former Modes of Treatment are examined and compared with one more rational and safe, effected without Rest and Confinement; together with Hints on a successful Method of treating some Scrofulous Tumours, the Mammery Abscess, and sore Nipples of Lying-in Women; Ob-

servations on the more common Disorders of the Eyes, and on Gangrene, boards, 6s, 8vo.

WADD's (Wm.) OBSERVATIONS on the best Mode of relieving Strictures in the Urethra; with Remarks on the frequent Inefficacy and ill Effects of Caustic Applications, 2d edition, enlarged, boards, 4s, 1811.

WHATELY's DESCRIPTION and TREATMENT of an AFFECTION of the TIBIA, induced by Fever; illustrated by a coloured engraving; by Thomas Whately, Member of the Royal College of Surgeons, London, 2s 6d

WHATELY's CASES of two extraordinary POLYPI removed from the Nose; the one by Excision with a new Instrument, the other by improved Forceps: with an Appendix describing an improved Instrument for the Fistula in Ano, with Observations on that Disease. Illustrated with a copper-plate, *sewed*, 2s. 8vo.

WHATELY's (T.) Improved METHOD of treating STRICTURES in the URETHRA, 2d edition, with additions, *boards*, 5s. 8vo.

WEBSTER's (Dr. Chas.) FACTS; tending to shew the Connexion of the Stomach with Life, Disease, and Recovery, sewed, 1s 6d

WITHERING's (William) OUTLINES of MINERALOGY, 8vo. sewed, 2s 6d.

WITHERING's (Dr. W.) ACCOUNT of the SCARLET FEVER and SORE THROAT, or Scarlatina Anginosa, particularly as it appeared at Birmingham in the year 1773; the 2d edition; to which are now prefixed, some Remarks on the Nature and Cure of the Ulcerated Sore Throat; 8vo. sewed, 2s. 6d.

WILSON's (Alexander) ESSAY on the Nature of Fever, 8vo. boards, 5s.

WRIGHT's HISTORY of the WALCHEREN REMITTENT; commencing with its advanced state, when most dangerous and destructive to the Soldiery, and concluding with its very favourable termination, effected by those means first proposed by the Author only to the Legislature, and to the late and present

Army Medical Board; with the Morbid Appearances on Dissection; also the sequels, Anæmia, Acholia, Egyptian Opthalmia, &c. &c. elucidated by Dissections. By Thomas Wright, M.D. and M.R.I.A. &c. &c. 8vo. price 10s 6d, boards

WHITE's (W.) OBSERVATIONS on the CONTRACTED INTESTINUM RECTUM, and the Mode of Treatment; accompanied with Cases, illustrative of the different Morbid Appearances attendant on the Complaint: to which are subjoined two engravings of the Disease. By W. White, Member of the Royal College of Surgeons, London, and one of the Surgeons to the City Infirmary and Dispensary, Bath; 8vo. bds. 3s. 6d.

YATMAN's FAMILIAR ANALYSIS of the Fluid capable of producing the Phenomena of Electricity of Galvanism or Combustion; with some Remarks on Simple Galvanic Girdles, and their Influence upon the Vital Principle of Animals; illustrated by Theories and Experiments of Aldini, Garnett, Davy, Young, Thompson, &c. &c. by Matthew Yateman, Esq. price 2s 6d.

YATMAN's (Matt.) LETTER to the Physicians and Surgeons of St. George's Hospital, on Mr. Davy's Simple Galvanic Girdles, considered as a Topical Assistant branch of Medicine in the correction of disordered living action, founded upon the Theories of Dr. Garnett and Mr. Davy, and confirmed by Practical Experience, 8vo. price 6d, 1811

Callow's Medical Subscription Library.

CONDITIONS.

An Annual Subscriber to pay	£2	2	0
Half a Year	1	5	0
Quarter of a Year	0	15	0
One Month	0	7	0

Annual Subscribers in Town or Country, paying Three Guineas per Annum, allowed an extra number of Books.

Two Octavos allowed at one Time; one Folio, or Quarto is reckoned equal to Two Octavos.

N.B. The Subscription to be paid at the time of subscribing.

G. Hayden, Printer, Brydges-street, Covent-garden.